

CrossMark
click for updates

Impact of various doses of curcumin on contrast media induced nephrotoxicity: a histopathological and biochemical study

Hossein Safi^{1,2}, Marzieh Kafeshani³, Esrafil Mansouri⁴, Mahmoud Rafieian-Kopaei⁵, Hamid Nasri^{2*}, Mehdi Nematbakhsh^{1*}

¹Water and Electrolytes Research Center & Department of Physiology, Isfahan University of Medical Sciences, Isfahan, Iran

²Department of Internal Medicine, Isfahan University of Medical Sciences, Isfahan, Iran

³Department of Community Nutrition, School of Nutrition and Food Sciences, Isfahan University of Medical Sciences, Isfahan, Iran

⁴Cellular and Molecular Research Center, Department of Anatomical Sciences, Faculty of Medicine, Ahvaz Jundishapur University of Medical Sciences, Ahvaz, Iran

⁵Medical Plants Research Center, Shahrekord University of Medical Sciences, Shahrekord, Iran

ARTICLE INFO

Article Type:
Original

Article History:
Received: 20 October 2017
Accepted: 1 January 2018
Published online: 10 January 2018

Keywords:
Curcumin
Contrast media
Nephropathy

ABSTRACT

Introduction: Contrast-induced nephropathy (CIN) is a cause of acute renal failure (RF) that can lead to certain complications such as chronic RF. Acute and chronic RF may need to dialysis and the need for dialysis, elongates hospital stay, increases costs, and finally increases mortality rate. Currently, the use of different antioxidants to prevent nephrotoxicity is the main focus of many studies in this field. Curcumin (CUR) is one of these compounds as the main isolated compound from the essential oil of turmeric underground stem. CUR has numerous pharmaceutical properties such as antioxidant, anticancer, and antimicrobial.

Objectives: The aim of this study was to investigate the effect of various doses of CUR on biochemical and histopathological parameters in CIN.

Materials and Methods: To conduct this study, 36 Wistar rats were divided into six groups of 6 each; negative control (NC) did not receive any drugs. Positive control (PC) was intraperitoneally injected with 10 ml/kg contrast media. CUR 50 and 250 mg/kg/d (CUR50, CUR250) groups were received intraperitoneally CUR suspended in corn oil for 10 days. CUR 50 or CUR 250 plus contrast media (CUR50 + CM, CUR250 + CM) groups were received intraperitoneally CUR + CM with 10 mL/kg/d of contrast media and CUR suspension for 10 days.

Results: The results showed that CUR caused a significant decrease in serum creatinine (Cr), blood urea nitrogen (BUN), and the percentage of debris, vacuolization, dilatation and renal tissue degeneration of renal tubules ($P < 0.05$).

Conclusion: We found the positive impact of CUR to protect kidney against the adverse effects of contrast media. Hence this compound might be useful against contrast induced acute kidney injury in patients at risk of contrast media induced nephrotoxicity.

Implication for health policy/practice/research/medical education:

In an experimental study we found the positive impact of curcumin to protect kidney against the adverse effects of contrast media. Hence this compound might be useful against contrast induced acute kidney injury in patients at risk of contrast media induced nephrotoxicity.

Please cite this paper as: Safi H, Kafeshani M, Mansouri E, Rafieian-kopaei MR, Nasri H, Nematbakhsh M. Impact of various doses of curcumin on contrast media induced nephrotoxicity: a histopathological and biochemical study. J Renal Inj Prev. 2018;7(x):x-x. DOI: 10.15171/jrip.2018.xx.

Introduction

Radiocontrast agents are common substances used to enhance the visibility of internal organs structures in X-ray-based imaging techniques such as computed tomography (CT), radiography, and fluoroscopy. Radiocontrast agents

are typically iodine or barium compounds. Recently, the number of imaging methods using contrast agents (radiocontrast media) has been increased. Applying these methods has led to increased prevalence of renal failure (RF), especially in high-risk populations including patients



*Corresponding authors: Prof. Hamid Nasri, MD; Email: hamidnasri@med.mui.ac.ir
Prof. Mehdi Nematbakhsh, Ph.D, Email: nematbakhsh@med.mui.ac.ir

with history of RF, congestive heart failure, and diabetes mellitus as well as the elderly. The incidence rate of RF caused by contrast agents (contrast-induced nephropathy [CIN]) following these imaging procedures is about 3%-5% in populations without risk factors while this rate may reach approximately 100% in people at risk (1,2). Several studies have revealed the effectiveness of medicinal plant extracts as a phytotherapeutic agent or as a protective agent in various diseases. Curcumin (CUR) (diferuloylmethane) is one of these compounds and is obtained from the milled Rhizomes of *Curcuma longa* Linn. It is consumed as a spice to give desirable flavor and color to food (3,4). CUR has numerous pharmaceutical properties such as antioxidant, anticancer, and antimicrobial (5-7). CUR also helps to reduce free radicals, inhibit lipids peroxidation, and increase the activity of superoxide dismutase (8,9). In addition, it has anti-inflammatory properties (10) and can reduce lipidemia and glycemia and improve Alzheimer disease (11).

Objectives

The purpose of this study was to investigate the protective effects of CUR in improving biochemical and histopathological parameters in CIN.

Materials and Methods

Experimental design

This study was performed on 36 Wistar rats weighing 200-250 g. Rats were purchased from the animal house of the Isfahan University of Medical Sciences. Animals were kept in standard conditions and maintained at room temperature ($25 \pm 2^\circ\text{C}$) and had free access to water and food. All the group's animals were left for 5 days without any intervention for environmental compatibility and climatic conditions and then underwent their respective interventions. They were divided randomly into six groups of 6 each; negative control (NC) did not receive any drugs. Positive control (PC) was intraperitoneally injected with 10 ml/kg/day contrast media. CUR 50 and 250 mg/kg/d (CUR50; T1, CUR250; T2) groups were received intraperitoneally CUR suspended in corn oil for 10 days. CUR50 or CUR250 plus contrast media (CUR50 + CM; T3, CUR250 + CM; T4) groups were received intraperitoneally CUR + CM with 10 mL/kg/d of contrast media and CUR suspension for 10 days.

Drug doses were selected according to a previous study (6). At the end of study, the rats were anesthetized as their blood samples were taken by heart puncture, and the animals were sacrificed. The kidney was removed for histopathological investigation.

Assessment of renal function

Blood serum was collected after centrifuging at 4000 rpm for 10 minutes. Serum urea and creatinine (Cr) were measured by a biochemical analyzer. Then, serum Cr and blood urea nitrogen (BUN) levels were measured using a commercially available kit (Pars Azmon, Iran) by an autoanalyzer (Hitachi 902, Japan) in accordance with the manufacturers' guidelines.

Histopathology analysis

Kidneys were removed placed in 10% formalin buffer for 24 hours. The specimens were subjected to sectioning and staining with hematoxylin & eosin method. Then, they were examined using an optical microscope (Olympus CH-2, Japan) by a nephropathologist who was blind to the grouping of the rats, and the percentage of flattening, degeneration, renal tubular dilatation, debris, and vacuolization was determined.

Ethical issues

The research was approved by Ethics Committee of Isfahan University of Medical. Prior to the experiment, the protocols were confirmed to be in accordance with the guidelines of Animal Ethics Committee of Isfahan University of Medical Sciences (code# IR.MUI.REC.1395.3.823). This study was extracted from internal medicine residency of Hossein Safi (Thesis# 395823).

Statistical analysis

The data were expressed as mean \pm standard deviation (SD). One-way analysis of variance (ANOVA) was used to compare differences between groups and followed by Tukey's multiple comparison test using SPSS 20 software. $P \leq 0.05$ was considered as the level of statistical significance.

Results

Biochemical parameters

It is apparent from Table 1 that serum Cr did not significantly increase in rats after contrast media

Table 1. The effect of curcumin on blood urea nitrogen, and serum creatinine in different groups

	Groups					
	NC	PC	CUR50 (T1)	CUR250 (T2)	CUR50 + CM (T3)	CUR250 + CM (T4)
BUN (mg/dL)	41.66 \pm 0.57	48.5 \pm 4.43	42.16 \pm 4.75	33.83 \pm 7.02 ^{ab}	40 \pm 4.61 ^{ab}	32.5 \pm 5.31 ^{ab}
Cr (mg/dL)	0.6 \pm 0	0.53 \pm 0.05	0.51 \pm 0.04 ^a	0.53 \pm 0.05 ^a	0.51 \pm 0.04 ^a	0.5 \pm 0 ^b

NC: Negative control (rats); PC: positive control (nephrotoxic rats); CUR 50 and CUR250 groups: nephrotoxic rats that were intraperitoneally injected with 50 mg/kg and 250 mg/kg curcumin, respectively; CUR50 +CM and CUR250 + CM: normal rats that were intraperitoneally injected with 50 mg/kg and 250 mg/kg curcumin, respectively; Cr, creatinine; BUN, blood urea nitrogen.

^a Significantly different compared to negative controls. ^b Significantly different compared to positive controls.

All values are express in mean \pm SD.

injection compared to negative control group, but BUN concentration increased significantly after contrast media injection ($P=0.023$). BUN concentration was decreased significantly in rat treated with 250 mg of CUR before and simultaneously with contrast media as compared to positive control group ($P<0.05$). Also treatment with 250 mg/kg CUR caused a significant decrease in Cr in rats with nephrotoxicity ($P=0.001$).

Histopathology

According to Figure 1, there was significant increase in the percentage of debris, degeneration, vacuolization of renal tubular cells and dilatation of tubular lumen, in kidneys of group receiving contrast media compared to control group ($P=0.002$, 0.002 , 0.004 , and 0.024 , respectively), while there was no significant difference in flattening of renal tubular cells between the NC group and the PC group ($P>0.05$). The percentage of tubular cell debris, degeneration, vacuolization and tubular lumen dilatation in nephrotoxic rats receiving 50 mg/kg and 250 mg/kg CUR decreased insignificantly compared to group receiving contrast media, while flattening did not change. Also, there was no significant difference in all lesions between healthy rats receiving 50 mg/kg or 250 mg/kg of CUR and other healthy rats ($P>0.05$).

Discussion

In the recent years, the frequency of experiments using contrast media has increased with the growth of the elderly population. The current study found that serum Cr was increased significantly after contrast media injection, however, BUN concentration did not significantly increase. The findings of the current study are consistent with previous study by Nasri et al, that found the contrast media contributed to increase in BUN, Cr, and renal lesions (12). The mechanisms of renal damage following exposure to contrast media have not yet been

known. However, previous studies reported that renal hemodynamics disturbances and direct damage to the renal tubular cells are involved in contrast media-induced renal damage. Contrast media reduces renal circulation especially in the medulla by increasing osmotic load and blood viscosity, and the resulting hypoxia leads to the production of oxygen free radicals. Free radicals cause damage to different cells including tubular cells and their components such as mitochondria that could ultimately induce cell necrosis (13). The oxygen free radicals play a role in tissue damage for various causes including tissue ischemia, toxins' effects, and immune-mediated damage all of which contribute to increasing the production of these harmful radicals (14).

Another important finding of our study was that CUR reduced serum Cr, BUN, and renal tissue lesions in rats with contrast media-induced nephropathy. Our finding confirmed the result of a previous study that investigated the effect of CUR on CIN in rats, and showed CUR increased the levels of glutathione, superoxide dismutase, catalase, and glutathione peroxidase that are important factors for oxidative stress at glomerular level, and finally cause cell apoptosis and RF (15). Venkatesan study showed that CUR intake in rats with adriamycin-induced nephrosis increased the urinary excretion of N-acetyl- β -D-glucosaminidase, fibrinogen, and glycosaminoglycan as well as the levels of glutathione and glutathione peroxidase in the kidney, and therefore protected the kidney (16). Some previous studies showed CUR exerted protective effects on the kidney and used to treat of diabetic nephropathy, chronic RF, and nephrotoxicity induced by gentamicin, adriamycin, chloroquine, and cisplatin (17-19). In a study, the administration of CUR in rats with nephropathy reduced the expression of chemokine genes regulated upon activation of normal T cell, MCP-1 (monocyte chemotactic protein 1), and AIF (allograft inflammatory factor-1) in the renal tubules,

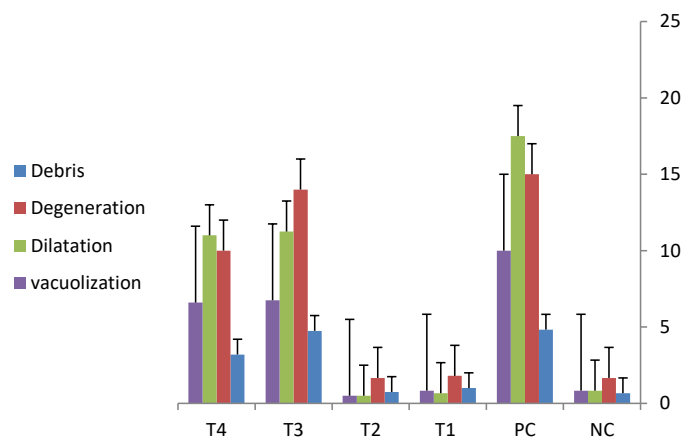


Figure 1. Data are expressed as mean \pm SD. The percentage of tubular cell debris, degeneration, vacuolization and tubular lumen dilatation of kidney, in different groups; NC; negative control (healthy rats); PC; positive control (nephrotoxic rats); CUR 50 (T1) and CUR250 (T2) groups; nephrotoxic rats that were intraperitoneally injected with 50 mg/kg and 250 mg/kg CUR, respectively; CUR50 + CM (T3) and CUR250 + CM (T4); normal rats that were intraperitoneally injected with 50 mg/kg and 250 mg/kg CUR, respectively. a, b, and c: Dissimilar letters in each column represent significant difference ($P<0.05$).

thereby inhibited and improved the inflammation of the renal tissue (20).

Various studies support the role of antioxidant agents in preventing contrast induced nephropathy and other causes of kidney damage (1). Today, because of the protective effects of phenolic compounds against reactive oxygen species and improving antioxidant system of the body, herbal treatments, such as applying supplements and plant extracts rich in polyphenols especially flavonoids and phenolic acids, are common throughout the world (21,22). CUR (C₂₁H₂₀O₆) is an active compound of turmeric (23,24), and its effects are due to anti-inflammatory activity by proinflammatory cytokines and inhibiting NF- κ B and its antioxidant properties. In addition, studies revealed that CUR had the antiapoptotic properties and prevented the development of renal tubular cell apoptosis by reducing the activation of proteins (25). Therefore CUR may consider an important factor in preventing CIN in rats.

Conclusion

Based on the results of this study, CUR was effective to improve contrast media induced nephropathy by decreasing of BUN, Cr, the percentage of tubular cell debris, degeneration, vacuolization and tubular lumen dilatation in kidney.

Authors' contribution

HS, HN and MN conducted the experimental procedures and helped to prepare the first draft of the article. MRF conducted the statistical analysis and prepared the primary draft. MK and EM revised the manuscript. MN designed and supervised the research and completed the final manuscript. All authors read and signed the paper.

Conflicts of interest

The authors declare no conflict of interest.

Ethical considerations

Ethical issues (including plagiarism, data fabrication, double publication) have been completely observed by the authors.

Funding/Support

This study was supported by Isfahan University of Medical Sciences. This study was extracted from internal medicine residency of Hossein Safi (Thesis# 395823).

References

- Colbay M, Yuksel S, Usilan I, Acarturk G, Karaman O, Bas O, et al. Novel approach for the prevention of contrast nephropathy. *Exp Toxicol Pathol.* 2010;62:81-9. doi: 10.1016/j.etp.2009.02.119.
- Fishbane S, Durham JH, Marzo K, Rudnick M. N-acetylcysteine in the prevention of radiocontrast-induced nephropathy. *J Am Soc Nephrol.* 2004;15:251-60.
- Al-Amoudi,Wael. Curcumin ameliorates nephrotoxicity

- and histopathological alterations induced by chlorpyrifos in albino rats. *FASEB J.* 2014; 28:690-5.
- Trujillo J, Chirino YI, Molina-Jijón E, Andérica-Romero AC, Tapia E, Pedraza-Chaverrí J. Renoprotective effect of the antioxidant curcumin: Recent findings. *Redox Biol.* 2013;1:448-56. doi: 10.1016/j.redox.2013.09.003.
- Goel A, Kunnumakkara AB, Aggarwal BB. Curcumin as "Curecumin": from kitchen to clinic. *Biochem pharmacol.* 2008;75:787-809. doi: 10.1016/j.bcp.2007.08.016.
- Aggarwal BB, Bhatt ID, Ichikawa H, Ahn KS, Sethi G, Sandur SK, et al. Curcumin: biological and medicinal properties. In: Ravindran PN, Nirmal Babu K, Shivaraman, ed. *Turmeric: the Genus Curcuma.* Boca Raton, FL: The CRC Press; 2006:297-368.
- Aggarwal BB, Sung B. Pharmacological basis for the role of curcumin in chronic diseases: an age-old spice with modern targets. *Trends Pharmacol Sci.* 2009;30:85-94. doi: 10.1016/j.tips.2008.11.002.
- Ataie A, Sabetkasaei M, Haghparast A, Moghaddam AH, Ataee R, Moghaddam SN. Curcumin exerts neuroprotective effects against homocysteine intracerebroventricular injection-induced cognitive impairment and oxidative stress in rat brain. *Trends Pharmacol Sci.* 2010;13:821-6. doi: 10.1089/jmf.2009.1278.
- Dairam A, Fogel R, Daya S, Limson JL. Antioxidant and iron-binding properties of curcumin, capsaicin, and S-allylcysteine reduce oxidative stress in rat brain homogenate. *J Agric Food Chem.* 2008;56:3350-6. doi: 10.1021/jf0734931.
- Wang Y, Yu C, Pan Y, Yang X, Huang Y, Feng Z, et al. A novel synthetic mono-carbonyl analogue of curcumin, A13, exhibits anti-inflammatory effects in vivo by inhibition of inflammatory mediators. *Inflammation.* 2012;35:594-604. doi: 10.1007/s10753-011-9350-4.
- Patumraj S, Wongeakin N, Sridulyakul P, Jariyapongskul A, Futrakul N, Bunnag S. Combined effects of curcumin and vitamin C to protect endothelial dysfunction in the iris tissue of STZ-induced diabetic rats. *Clin Hemorheol Microcirc.* 2006;35:481-9.
- Nasri H, Tavakoli M, Ahmadi A, Baradaran A, Nematbakhsh M, Rafieian-Kopaei M. Ameliorative effect of melatonin against contrast media induced renal tubular cell injury. *Pak J Med Sci.* 2014;30:261.
- Gazi S, Altun A, Erdogan O. Contrast-induced nephropathy: preventive and protective effects of melatonin. *J Pineal Res.* 2006;41:53-7. doi:10.1111/j.1600-079x.2006.00336.x
- Zhou X, Zhang J, Xu C, Wang W. Curcumin ameliorates renal fibrosis by inhibiting local fibroblast proliferation and extracellular matrix deposition. *J Pharmacol Sci.* 2014;126(4):344-50. doi: 10.1254/jphs.14173FP.
- Buyuklu M, Kandemir FM, Ozkaraca M, Set T, Bakirci EM, Topal E. Protective effect of curcumin against contrast induced nephropathy in rat kidney: what is happening to oxidative stress, inflammation, autophagy and apoptosis. *Eur Rev Med Pharmacol Sci.* 2014;18:461-70.
- Venkatesan N, Punithavathi D, Arumugam V. Curcumin prevents adriamycin nephrotoxicity in rats. *Br J Pharmacol.* 2000;129:231-4. doi: 10.1038/sj.bjp.0703067
- Ahmida MH. Protective role of curcumin in nephrotoxic oxidative damage induced by vancomycin in rats. *Exp Toxicol Pathol.* 2012;64:149-53. doi: 10.1016/j.etp.2010.07.010.

18. Ugur S, Ulu R, Dogukan A, Gurel A, Yigit IP, Gozel N, et al. The renoprotective effect of curcumin in cisplatin-induced nephrotoxicity. *Ren Fai*. 2015;37:332-6. doi: 10.3109/0886022X.2014.986005.
19. Trujillo J, Chirino YI, Molina-Jijón E, Andérica-Romero AC, Tapia E, Pedraza-Chaverrí J. Renoprotective effect of the antioxidant curcumin: Recent findings. *Redox Biol*. 2013;17:448-56. doi: 10.1016/j.redox.2013.09.003.
20. Shoskes DA. Effect of bioflavonoids quercetin and curcumin on ischemic renal injury: a new class of renoprotective agents. *Transplantation*. 1998;66:147-52.
21. Subapriya R, Kumaraguruparan R, Abraham S, Nagini S. Protective Effects of Ethanolic Neem Leaf Extract on N-Methyl-N'-nitro-N-nitrosoguanidine-Induced Genotoxicity and Oxidative Stress in Mice. *Drug Chem Toxicol*. 2004; 27:15-26.
22. Gupta SC, Patchva S, Aggarwal BB. Therapeutic roles of curcumin: lessons learned from clinical trials. *AAPS J*. 2013;15:195-218. doi: 10.1208/s12248-012-9432-8.
23. Weisburger JH. Antimutagenesis and anticarcinogenesis, from the past to the future. *Mutat Res*. 2001;480:23-35.
24. Ghosh SS, Gehr TW, Ghosh S. Curcumin and chronic kidney disease (CKD): major mode of action through stimulating endogenous intestinal alkaline phosphatase. *Molecules*. 2014;19:20139-56. doi: 10.3390/molecules191220139.
25. Topcu-Tarladacalisir Y, Sapmaz-Metin M, Karaca T. Curcumin counteracts cisplatin-induced nephrotoxicity by preventing renal tubular cell apoptosis. *Ren Fail*. 2016;38:1741-8. doi: 10.1080/0886022X.2016.1229996.

Copyright © 2018 The Author(s); Published by Nickan Research Institute. This is an open-access article distributed under the terms of the Creative Commons Attribution License (<http://creativecommons.org/licenses/by/4.0>), which permits unrestricted use, distribution, and reproduction in any medium, provided the original work is properly cited.