



Evaluation of sacral dimple association with urodynamic findings in children with recurrent urinary tract infection

Elham Emami¹, Mostafa Sharifian², Masoumeh Mohkam², Atrin Oroojeni^{3*}, Reza Dorali⁴, Pedram Javanmard⁵

¹Pediatric Nephrology Research Center (PNRC), Faculty of Medicine, Emam Hosein Hospital, Shahid Beheshti University of Medical Sciences, Tehran, Iran

²Pediatric Nephrology Research Center (PNRC), Faculty of Medicine, Shahid Beheshti University of Medical Sciences, Tehran, Iran

³Clinical Research Development Unit, Golestan Hospital, Ahvaz University of Medical Sciences, Ahvaz, Iran

⁴Janbazan Medical and Engineering Research Center (JMERC), Tehran, Iran

⁵Division of Endocrinology, Diabetes, and Bone Disease, Department of Medicine, Icahn School of Medicine at Mount Sinai, New York, USA

ARTICLE INFO

Article Type:

Original

Article History:

Received: 7 December 2021

Accepted: 1 March 2022

Published online: 4 March 2022

Keywords:

Urinary tract infection

Urodynamic

Neurogenic bladder

Sacral dimple

ABSTRACT

Introduction: Urinary tract infections (UTIs) are among the most important diseases of children. UTI timely diagnosis and treatment is essential to prevent renal failure.

Objectives: This study aims to investigate the association of sacral dimples with recurrent UTIs and urodynamic findings in a group of pediatric patients.

Patients and Methods: This case-control study was conducted on children aged one month to fifteen years old with recurrent UTIs. The association of sacral dimples with recurrent UTIs and urodynamic findings were studied.

Results: In total, 229 patients with recurrent UTIs were recruited. One hundred thirty-one patients were in the case group (with sacral dimple), and 98 patients were in the control group (without sacral dimple). One-hundred and nine children (82.2%) in the case group and 56 children (57.1%) in the control group had abnormal voiding cystourethrography (VCUG) ($P < 0.001$). Forty patients in the case group and 29 patients (29.6%) in the control group had abnormal dimercaptosuccinic acid (DMSA) scan in the first study ($P = 0.568$). Twenty-two patients (16.8%) in the case group and 13 patients (13.3%) in the control group had renal scarring ($P = 0.578$). Urodynamic findings were abnormal in 117 children (89.3%) in the case group and 70 children (71.4%) in the control group ($P = 0.001$, OR=3.34, 95% CI: 1.65-6.78).

Conclusion: In this study, abnormal uroflowmetry and bladder compliance were significantly more common in children with recurrent UTIs with sacral dimple in comparison to recurrent UTIs in patients without sacral dimple. It is recommended that in cases of sacral dimples, patients should undergo a urodynamic study to detect bladder dysfunction.

Implication for health policy/practice/research/medical education:

In our cross sectional study we found that, the number of abnormal urodynamic findings in children with recurrent urinary tract infections and sacral dimple was 25% more than children without sacral dimples.

Please cite this paper as: Emami E, Sharifian M, Mohkam M, Oroojeni A, Dorali R, Javanmard P. Evaluation of sacral dimple association with urodynamic findings in children with recurrent urinary tract infection. J Renal Inj Prev. 2022; 11(2): e9622. doi: 10.34172/jrip.2022.9622.

Introduction

Spinal cord defects are the second most common anomalies after cardiac abnormalities, with an incidence of 1 per 1000 live births (1,2). It is estimated that about 300 000 infants are born with these anomalies each year (3-6). Neural tube defects at the end of the fourth week of pregnancy lead to different anomalies such as spina bifida

and myelomeningocele (7-9). One of the most important signs related to the abnormality of the spine or spinal cord is the presence of sacral dimples. A sacral dimple is a small, usually shallow indentation in the back, just above or within the crease of the buttocks, that occurs in above 50% of neonates with spinal dysraphism (9,10). In addition to physical examination, ultrasonography (only

for newborns) and magnetic resonance imaging (MRI) can confirm neurological malformations. Following neurological malformations, urinary system disorders are the most complications (4,10). Urinary tract infection (UTI) is one of the most problems in childhood. However, the following criteria have been found to differentiate best between dimples that require further evaluation and those that require only routine follow-up evaluations; multiple dimples, dimple diameter larger than 5 mm, dimples located >2.5 cm above the anal verge, and dimples associated with other cutaneous markers (11,12). Gram-negative bacteria such as *E. coli*, *Klebsiella*, *Proteus*, *Enterobacter*, *Pseudomonas*, and *Serratia* are the most commonly involved organisms in UTI. One-third to one-half of children with UTIs experience relapse at least once. Moreover, permanent renal scarring may occur in about 50% of infected children, especially those with recurrent UTIs (3,9,13).

Objectives

Few studies have been conducted to investigate the association between recurrent UTIs and the presence of sacral dimples. The present study aims to investigate the association of sacral dimples with recurrent UTIs and urodynamic findings in a sample of Iranian pediatric patients.

Patients and Methods

Study design and setting

This case-control study was conducted on 229 children with at least two episodes of UTI who were admitted to the nephrology clinic at Mofid pediatric hospital (2018 to 2019), Tehran, Iran. Their age ranged from one month to 15 years. In total, 131 patients with sacral dimples and

undescended testicles (UDT) were selected as the case group, and 98 patients with UDT and without sacral dimples were recruited as the control group. In both groups, urine samples were collected supra-pubically in children below the age of one year and by a urinary catheter or through the midstream urine for toilet-trained children above the age of one year. Moreover, renal and bladder ultrasonography to identify renal and urinary anomalies, urodynamic studies (UDS), cystography [voiding cystourethrography (VCUG)], and dimercaptosuccinic acid (DMSA) scan were conducted. Patients with genetic diseases, brain damage, or other diseases were excluded from the study.

Data analysis

All statistical analyses were conducted using Statistical Package for Social Sciences (SPSS) version 25. Numerical variables were expressed as mean \pm standard deviation (SD). Categorical variables were presented as frequency (percentages). Independent samples t-test, chi-square, and Fisher's exact test were employed to compare variables in both groups. Statistical significance was defined as a *P* value < 0.05.

Results

Demographic and primary characteristics of patients in both case and control groups are presented in Table 1.

One hundred nine children (82.2%) in the case group and 56 children (57.1%) in the control group had abnormal VCUG. Details of the VCUG findings are shown in Table 2.

Findings of the DMSA scan were normal in 69 (70.4%) children in the case group and 87 (66.4%) children in the control group (*P*=0.568). Urine cultures were normal

Table 1. Demographic characteristics of patients in the case and control groups

Variables	Case group (n=131)	Control group (n=98)	<i>P</i> value
Gender (male)	37 (28.2%)	26 (26.5%)	0.881
Age first UTI (year)	7.9 \pm 5.8	12.8 \pm 5.8	<0.001
UTI recurrence times	4.1 \pm 2.0	3.3 \pm 0.9	0.005

UTI, urinary tract infection.

Table 2. VCUG findings in the case and control groups

VCUG Findings	Case group	Control group	<i>P</i> value
Normal	22 (16.8%)	42 (42.9%)	<0.001
VUR	109 (83.2%)	56 (57.1%)	<0.001
Right VUR	48 (36.6%)	36 (36.7%)	1.0
Left VUR	57 (43.5%)	37 (37.8%)	0.417
Vertical bladder or spinning top	38 (29.0%)	13 (13.3%)	0.006
Thick bladder wall in ultrasonography	8 (6.1%)	3 (3.1%)	0.360
Residual urine	22 (16.8%)	11 (11.2%)	0.259
Spina bifida	12 (9.2%)	2 (2%)	0.028

VUR, vesicoureteral reflux.

in all patients in both groups ($P < 0.001$). No significant difference was observed between the two groups in terms of the neurogenic bladder ($P = 0.333$) and hydronephrosis ($P = 0.764$) according to ultrasound findings; however, the fullness of the kidney was higher in the case group (2.9%) compared to the control group (9.2%) ($P = 0.007$). Urodynamic study was normal in 28 (28.6%) patients in the case group and 14 (10.7%) patients in the control group (Figure 1). Further details about abnormal findings of the DMSA scan, urine culture, and ultrasonographic and urodynamic assessments are presented in Table 3.

In our study, the mean age of children at the first UTI was significantly lower in children with sacral dimples in comparison to children without dimples (7.9 ± 5.8 versus 12.8 ± 5.8 , $P < 0.001$). It was also found that the frequency of abnormal VCUG findings in children with sacral

dimples (82.2%) was significantly higher than children without dimples (57.1%) (Odds ratio [OR] = 3.72, $P < 0.001$). VCUG findings indicated that the frequency of vertical bladder or spinning top (OR = 2.67, $P = 0.006$) and spina bifida (OR = 4.84, $P = 0.028$) was higher in children with sacral dimples, while such findings are a marker of neurogenic bladder. No significant difference was found in DMSA scan results in children with sacral dimples and the control group (33.6% versus 29.6%; OR = 1.20, $P = 0.568$). However, the frequency of new scars was more common in children with sacral dimples (OR = 4.10, $P = 0.024$). In the early months of life, a DMSA scan may show no scars since scars are organized in the course of time. In this study, new scar formation was more common in the dimple group due to the simultaneous presence of neurogenic bladder in these patients. Additionally, DMSA findings in 40 children with sacral dimples indicated decreased kidney function, which involved the right kidney in 18 children (45%) and the left kidney in 18 children (45%), and both kidneys in four children (10%). Reduced renal function in 24 children without sacral dimple involved the right kidney in seven children (29.2%), the left kidney in 12 children, and both kidneys in six children (25%). There was a significant difference in renal fullness in the case group in comparison to the control group (OR = 2.94; $P = 0.007$). The urodynamic result showed children with sacral dimples had more abnormal urodynamic findings compared with the control group (89.3% versus 71.4%; OR = 3.34, 95% CI: 1.65-6.78, $P = 0.001$). Moreover, in cytometry, the frequency of abnormal cytometry (OR = 2.35, 95% CI: 1.11-4.96; $P = 0.024$) and low-bladder

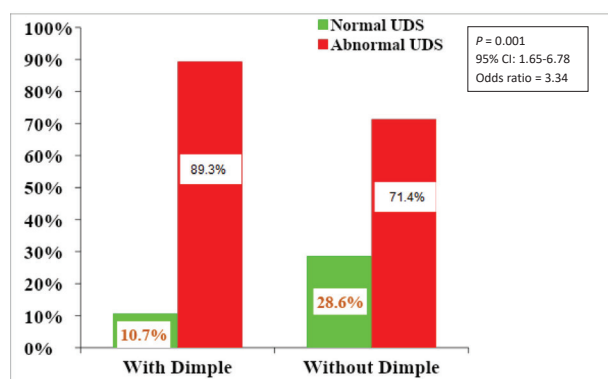


Figure 1. Frequency of abnormal urodynamic study in children with and without sacral dimple.

Table 3. DMSA, urine culture, US and UDS finding in case and control groups

Variables	Case group	Control group	P value	
DMSA	Normal	87 (66.4%)	69 (70.4%)	0.568
	Scar	22 (16.8%)	13 (13.3%)	0.578
	New scar formation	15 (11.5%)	3 (3.1%)	0.024
Urine culture findings	<i>E. coli</i>	36 (27.5%)	47 (48%)	<0.001
	<i>Klebsiella</i>	16 (12.2%)	11 (11.2%)	<0.001
	<i>Enterococcus</i>	13 (9.9%)	2 (2%)	<0.001
	ESBL <i>E. coli</i>	16 (12.2%)	1 (1%)	<0.001
	<i>Citrobacter</i>	13 (9.9%)	5 (5.1%)	<0.001
US Findings	Neurogenic Bladder	32 (24.4%)	18 (18.4%)	0.333
	Fullness of Kidney	30 (22.9%)	9 (9.2%)	0.007
	Hydronephrosis	34 (26.0%)	28 (28.6%)	0.764
UDS Finding	Normal	14 (10.7%)	28 (28.6%)	0.001
	Abnormal PFR	44 (33.6%)	26 (26.5%)	0.251
	Abnormal Uroflowmetry	30 (22.9%)	11 (11.2%)	0.024
	Low bladder compliance	56 (42.7%)	24 (24.5%)	0.005
	Capacity abnormality	29 (22.1%)	17 (17.3%)	0.408
	Uninhibited bladder contraction	24 (18.3%)	15 (15.3%)	0.597
	Detrusor sphincter dyssynergia	14 (10.7%)	12 (12.2%)	0.834

UDS; urodynamic study, US; ultrasonography, ESBL; extended-spectrum beta-lactamase.

compliance were more common in children with sacral dimples (OR=2.30, 95% CI: 1.29-4.10; $P=0.005$).

Discussion

In the present study, recurrent UTIs, abnormal sonographic findings (more urine residual volume, more bladder wall thickness, and greater hydronephrosis) and abnormal VCUG (greater vesical urethral reflux, vertical bladder, and spinning top deformity), and abnormal uroflowmetry and cystometry (detrusor sphincter dyssynergia, abnormal capacity, and compliance) were significantly more common in the children with recurrent UTI and sacral dimple compared with children with recurrent UTI patients without sacral dimple. DMSA scan findings show more new scar formation in the group of patients with a sacral dimple.

Sharifian et al demonstrated urinary tract problems in patients with spinal dysraphism. They concluded that 72% of these patients had at least one episode of pyelonephritis, and 34% of them had severe hydronephrosis. Moreover, they have indicated that the prevalence of vesicoureteral reflux and neurogenic bladder in patients with spinal dysraphism was 35% and 80%, respectively (14).

In the present study, the prevalence of recurrent UTIs in girls was 72.5%. However, no significant difference was shown between genders and the presence of sacral dimples. However, isolated dorsal dermal pits do not require a radiographic or surgical evaluation and treatment. We highlight the need for evaluation of such pits because of the risk of progressive bladder dysfunction. The present study aimed to diagnose and prevent such bladder sequel before any symptoms lead to irreversible damage, which is consistent with the study by Weprin et al (5).

Results of the present study indicated that some types of microorganisms such as extended-spectrum beta-lactamase (ESBL), *E. coli*, *Enterococcus*, and *Citrobacter* were more prevalent in urine cultures in the case group in comparison with the control group.

However, the prevalence of *E. coli* as the most common germ in UTIs was common in both groups (27.5% and 48%). Gram-negative bacteria such as *E. coli*, *Klebsiella*, *Proteus*, *Enterobacter*, *Pseudomonas*, and *Serratia* are the most commonly involved organisms in UTI and in patients without urinary tract abnormality or dysfunction; while atypical germs such as ESBL, *E. coli*, *Enterococcus*, and *Citrobacter* are not expected in common UTIs. Results of the present study showed a higher rate of atypical germs in the dimple group atypical germs.

The incidence of abnormal ultrasonography in children with sacral dimples (55.7%) was not significantly different from children without dimples (52.0%).

Urodynamic results showed children with sacral dimples had more abnormal urodynamic findings compared with the control group. Moreover, the frequency of abnormal cystometry and low-bladder compliance was more common in children with sacral dimples.

Our results demonstrated that children with sacral dimples experience a higher incidence of UTI and have the first episode at earlier ages.

Conclusion

Lumbar column inspection and spinal examination are recommended in children with recurrent UTIs for any abnormality such as post anal dimple and hair tuft. In case of a sacral dimple, patients should undergo urodynamic studies for bladder dysfunction; therefore, the neurogenic bladder should be diagnosed in the early stages to prevent recurrent infections with typical or maybe atypical germs, kidney scarring, and its consequences such as hypertension due to scar and in some cases renal failure. Circumstantial diagnosis is necessary to prevent irreversible consequences such as renal parenchymal damage and scar formation.

Limitations of the study

This study was conducted with small sample size. More studies with greater sample sizes with cohort design are needed to find causality relationships.

Authors' contribution

EE and MS were the principal investigators of the study. MM participated in data collection. AO, PJ and RD conducted further edits. All authors participated in preparing the final draft of the manuscript. All authors read and approved the content of the manuscript and confirmed its accuracy.

Conflicts of interest

The authors declared no conflicts of interest.

Ethical issues

The research followed the tenets of the Declaration of Helsinki. This study was approved by the ethics committee of Shahid Beheshti University of Medical Sciences (#IR.SBMU.MSP.REC.1398.301). This study is derived from pediatric nephrology fellowship thesis of Elham Emami. All children's parents signed informed consent prior to the initiation of the study.

Funding/Support

This study was financially supported by the Vice-Chancellor for Research of *Shahid Beheshti University of Medical Sciences*.

References

1. Foxman B, Brown P. Epidemiology of urinary tract infections: transmission and risk factors, incidence, and costs. *Infect Dis Clin North Am*. 2003;17:227-41. doi: 10.1016/s0891-5520(03)00005-9.
2. Stull TL, LiPuma JJ. Epidemiology and natural history of urinary tract infections in children. *Med Clin North Am*. 1991;75:287-97. doi: 10.1016/s0025-7125(16)30454-0.
3. Painsil E. Update on recent guidelines for the management

- of urinary tract infections in children: the shifting paradigm. *Curr Opin Pediatr.* 2013;25:88-94. doi: 10.1097/MOP.0b013e32835c14cc.
4. Jacobson SH, Eklof O, Eriksson CG, Lins LE, Tidgren B, Winberg J. Development of hypertension and uraemia after pyelonephritis in childhood: 27 year follow up. *BMJ.* 1989;299:703-6. doi: 10.1136/bmj.299.6701.703.
 5. Weprin BE, Oakes WJ. Coccygeal pits. *Pediatrics.* 2000; 105:E69. doi: 10.1542/peds.105.5.e69.
 6. Williams LJ, Rasmussen SA, Flores A, Kirby RS, Edmonds LD. Decline in the prevalence of spina bifida and anencephaly by race/ethnicity: 1995-2002. *Pediatrics.* 2005; 116:580-6. doi: 10.1542/peds.2005-0592.
 7. Wiswell TE, Tuttle DJ, Northam RS, Simonds GR. Major congenital neurologic malformations. A 17-year survey. *Am J Dis Child.* 1990;144:61-7. doi: 10.1001/archpedi.1990.02150250071035.
 8. Detrait ER, George TM, Etchevers HC, Gilbert JR, Vekemans M, Speer MC. Human neural tube defects: developmental biology, epidemiology, and genetics. *Neurotoxicol Teratol.* 2005;27:515-24. doi: 10.1016/j.ntt.2004.12.007.
 9. Botto LD, Moore CA, Khoury MJ, Erickson JD. Neural-tube defects. *N Engl J Med.* 1999; 341:1509-19. doi: 10.1056/NEJM199911113412006.
 10. Hertrampf E, Cortes F, Erickson JD, Cayazzo M, Freire W, Bailey LB, et al. Consumption of folic acid-fortified bread improves folate status in women of reproductive age in Chile. *J Nutr.* 2003; 133:3166-9. doi: 10.1093/jn/133.10.3166.
 11. Boone D, Parsons D, Lachmann SM ST. Spina bifida occulta: lesion or anomaly? *Clin Radiol.* 1985;36:159-61. doi: 10.1016/s0009-9260(85)80100-8.
 12. Soonawala N, Overweg-Plandsoen WC, Brouwer OF. Early clinical signs and symptoms in occult spinal dysraphism: a retrospective case study of 47 patients. *Clin Neurol Neurosurg.* 1999;101:11-4. doi: 10.1016/s0303-8467(98)00073-0.
 13. Medina LS, Crone K, Kuntz KM. Newborns with suspected occult spinal dysraphism: a cost-effectiveness analysis of diagnostic strategies. *Pediatrics.* 2001;108:E101. doi: 10.1542/peds.108.6.e101.
 14. Shariffian N, Envaripoor N, Zili A. Urinary tract disease in individuals with espinal disraphism; *Paekistien Sci J Med.* 2015;24:740-62.

Copyright © 2022 The Author(s); Published by Nickan Research Institute. This is an open-access article distributed under the terms of the Creative Commons Attribution License (<http://creativecommons.org/licenses/by/4.0>), which permits unrestricted use, distribution, and reproduction in any medium, provided the original work is properly cited.