



Phytotherapy and phytopharmacology for reduction of cyclophosphamide-induced toxicity in the male urinary system

Mohammad Afkhami-Ardakani¹, Shapour Hassanzadeh¹, Rasoul Shahrooz¹, Majid Asadi-Samani^{2*}, Ebrahim Latifi³, Tahra Luther⁴

¹Department of Basic Sciences, Faculty of Veterinary, Urmia University, Urmia, Iran

²Student Research Committee, Shahrekord University of Medical Sciences, Shahrekord, Iran

³Ferdowsi University of Mashhad, Mashhad, Iran

⁴Department of General Surgery, University of Michigan, Ann Arbor, MI, USA

ARTICLE INFO

Article Type:
Review

Article History:

Received: 14 November 2016

Accepted: 27 January 2017

Published online: 5 February 2017

Keywords:

Medicinal plants,
Cyclophosphamide
Male reproductive system
Chemotherapy
Polyphenols

ABSTRACT

This systematic review was conducted to evaluate the protective effects and the role of medicinal plants and their derivatives in reducing the cyclophosphamide-induced side effects in the male urinary system. For this systematic review, the search terms cyclophosphamide, urinary system, male reproductive system, toxicity, cancer, chemotherapy, and side effects in combination with the terms medicinal plants, herbal medicines, and natural compounds were used to search for the relevant publications indexed in Google Scholar, Information Sciences Institute, Scopus, and PubMed. Fifteen plant extracts, two essential oils, three plant active components, and two herbal medicines were introduced. According to the results, plants with antioxidant compounds, such as flavonoids, are able to reduce cyclophosphamide-induced testicular toxicity. It is therefore recommended that the plants with significant antioxidant effects be prescribed alongside cyclophosphamide and their effects be compared with other plants and their derivatives.

Implication for health policy/practice/research/medical education:

The introduced medicinal plants in this systematic review can reduce cyclophosphamide induced toxicity in testicular tissue and therefore exert their protective effects on the drugs' side effects. They can be used for discovering new drugs by evaluating their effects in clinical trials.

Please cite this paper as: Afkhami-Ardakani M, Hassanzadeh S, Shahrooz R, Asadi-Samani M, Latifi M, Luther T. Phytotherapy and phytopharmacology for reduction of cyclophosphamide-induced toxicity in the male urinary system. J Renal Inj Prev. 2017;6(3):164-170. DOI: 10.15171/jrip.2017.32.

Introduction

Cyclophosphamide (CP) has been used as an anticancer agent since 1950. Besides that, this drug exerts immunomodulatory effects (1) and is used to treat different tumors, patients with organ transplant, and autoimmune diseases such as rheumatoid arthritis and multiple sclerosis (2). CP regulates the immune system through inducing differentiation of Th17 cells (3), decreasing in regulatory T cells (4), and increasing in interferon type I (5). First, CP in the liver is metabolized to 4-hydroxycyclophosphamide by cytochrome P450, and then enters into cells and

spontaneously degrades to phosphoramidate-mustard and acrolein (6,7). Phosphoramidate-mustard alkylates DNA through alkyl group's attaching to DNA, and prevents its replication and inhibits tumor cells growth. However, acrolein exerts toxic effects on the body's healthy cell because it produces reactive oxygen species and nitric oxide, and leads to production of peroxynitrite that destroys intracellular lipids, proteins, and DNA (8). Different studies have reported certain side effects of CP. For example, a study demonstrated that treatment with a single dose (100 mg/kg) of CP caused induction



*Corresponding author: Majid Asadi-Samani, Email: biology_2011@yahoo.com

of oxidative stress in mouse liver (2). Moreover, treatment with CP causes hemorrhagic cystitis, a type of urinary tract infection and causes hemorrhage, angiogenesis, and lower urinary tract necrosis (9,10). CP-induced toxic effects on gonads are considered relevant side effects of chemotherapy with CP that can lead to infertility. Increased incidence of sperm abnormalities such as oligospermia and azoospermia in patients undergoing treatment with CP confirms this argument (11). In addition, CP injection caused damage to sex cells in male rats. Moreover, the shape of chromatin in these cells changes, and in the case of fertilization, the genetics of the egg changes and hence fetal death occurs (12,13).

According to the available evidence, despite having significant pharmaceutical effects in treating different diseases, especially cancer, CP causes several side effects particularly in the reproductive system. This has limited the use of this drug. However, since many studies have been conducted to identify nature-based products to reduce the side effects of CP, this review seeks to review the effects of medicinal plants and their derivatives on the male urinary system in a focused manner, to report their protective effects on associated complications to offer an analysis of the plants' role in reducing these complications. Plants have long been used by local people to prevent many diseases and side effects (14-21). Also their effects have already been confirmed in scientific investigations (22-26).

Materials and Methods

To conduct this review article, the relevant search terms consisting of cyclophosphamide, male reproductive

system, toxicity, cancer, chemotherapy, and side effects combined with medicinal plants, herbal medicines, and natural compounds were used to search for relevant publications indexed in Information Sciences Institute, PubMed, Scopus, and Google Scholar between 2000 and 2016. To decide on the eligibility of an article for inclusion in this analysis, the abstracts were previewed. If the article was useful and required for this review, then its full text was retrieved for more detailed analysis.

The inclusion criteria were: having an abstract in English language, studying CP-induced toxicity with emphasis on the male genital tract, using medicinal plants and their active compounds to reduce CP-induced toxicity, and having an experimental design (in vitro and in vivo).

In a primary search using the above search terms, 653 abstract were selected for analysis. After setting aside duplicate publications (n: 75), the rest of the abstracts (n: 578) were studied according to the titles. Of these abstracts, 482 abstracts were excluded because of being written in a non English language, not studying medicinal plants, and not using cyclophosphamide to induce toxicity. The full text of 96 articles were retrieved and analyzed. Afterwards, 74 articles were excluded because of adopting inappropriate study design, not having a controlled design, not reporting plant-based active compounds, and not focusing on the male reproductive system. Finally, 22 articles were included in the review (Figure 1).

Phytotherapy and phytopharmacology

Of these articles, 15 described plant-based extracts, three plant-based active compounds, two essential oils, and two herbal medicines (27-48) (Table 1).

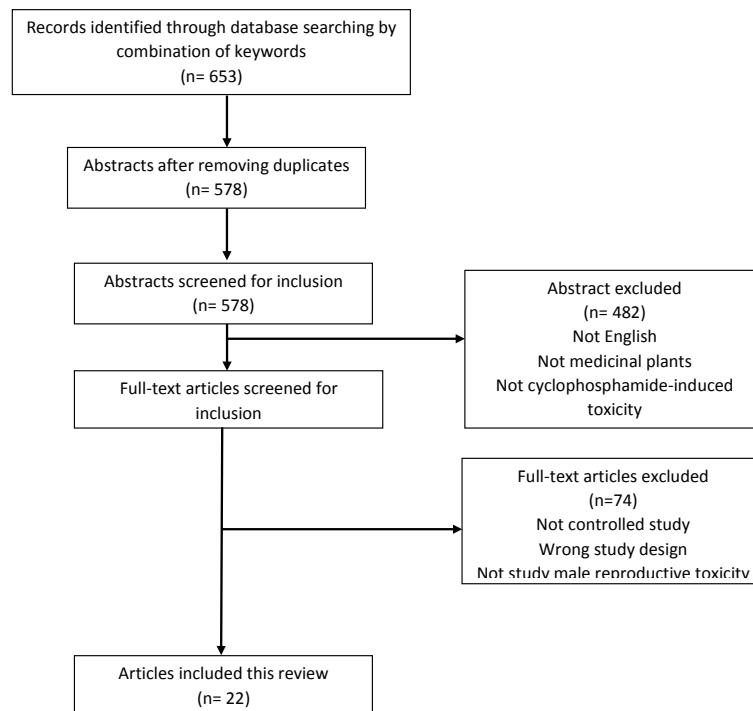


Figure 1. Flow chart of systematic search of selection studies

Table 1. Medicinal plants and their derivatives for reduction of cyclophosphamide-induced toxicity in the male urinary system

Medicinal plants/ compound(s)	Study design	Animal	Phytotherapy	Dose and delivery of cyclophosphamide(CP)	Dose and delivery of phytotherapy	Results	Ref.
<i>Nigella sativa</i>	32 days; 4 groups (n = 6)	Male mice	Ethanol extract	200 mg/kg; Intraperitoneal injection	10 mg/kg; Intraperitoneal injection	Improved histomorphology of the testes, and in the morphology of the sperm; Increase in the sperm count; Decrease in the acrosome-reacted sperm.	(28)
<i>Camellia sinensis</i>	14 days; 3 groups (n=not mention)	Male mice	Infusion	100 mg/kg; Single dose in 14th day; Intraperitoneal injection	250 mg/kg; Oral	Decrease in the malondialdehyde (MDA) level in testis tissue, in the protein carbonyl level in testis tissue; in the DNA damage index in testis and epididymis tissue; Significant increase in the count, motility and integrity of sperm, in the activity of glutathione peroxidase (GPx) and glutathione S-transferase (GST) in testis, and in the concentration of 17 β -hydroxysteroid dehydrogenase.	(27)
<i>American ginseng</i>	42 days; 4 groups (n=7)	Male rats	Extract	6.1 mg/kg; Intraperitoneal injection	500 mg/kg; Oral	Increase in epididymal sperm count, and in motility of epididymal sperm; Decrease in dead epididymal sperm and abnormal epididymal sperm.	(29)
Ginger and Pumpkin seed	42 days; 4 groups (n=10)	Male rats	Extracts	100 mg/kg; Intraperitoneal injection	300 mg/kg; oral	Significant increase in the count of spermatogonia, spermatocytes and sperm; Significant increase in the serum level of antioxidant.	(30)
<i>Cinnamomum zeylanicum</i> Nees	RCT; 21 days; 5 groups (n=7)	Male rats	Hydroalcoholic extract	5 mg/kg; Intraperitoneal injection	50 , 100 and 200 mg/ kg; Oral	Significant increase in LH level; Significant increase in testosterone level; Significant decrease in FSH level; Significant increase in weight of testes.	(31)
<i>Crataegus monogyna</i>	28 days; 4 groups (n=6)	Male rats	Aqueous extract	5 mg/kg; Oral	20 mg/kg; Oral	Significant increase in the weight of testes, epididymis, seminal vesicle and ventral prostate, in the tubule differentiation index (TDI) and spermiation index (SPI); in the level of FSH and LH, and in the sperm count and motility; Significant decrease in the number of abnormal and dead sperm, and in the level of testosterone; Improved histomorphology of testis.	(32)
<i>Aegle marmelos</i>	28 days; 5 groups (n=5)	Male mice	Fruit extract	50 mg/kg; once week; Intraperitoneal injection	200, 400 and 600 mg/ kg; Oral	Significant decrease in the percentage of aberrant sperm; and in the percentage of abnormal metaphase in the meiotic cells of testis.	(33)
<i>Phyllanthus fraternus Webster</i>	35 days; 6 groups (n=6)	Male mice	Aqueous extract	200 mg/kg; Once week; Intraperitoneal injection	200, 300 and 400 mg/kg Once week Oral	Significant increase in the sperm count, motility and viability and gonadosomatic index (GSI), and in the activity of superoxide dismutase (SOD) and catalase (CAT) in testis; Improved histomorphology of testis, and in the DNA damage of sperm; Significant decrease in the activity of Lipid peroxidation (LPO).	(34)
<i>Achillea millefolium</i>	28 days; 4 groups (n=6)	Male rats	Aqueous extract	5 mg/kg; Oral	1.2 g/kg; Oral	Significant increase in the weight of testes and epididymis, in the Sertoli cell index, meiotic index and repopulation index, in the serum level of testosterone, in the count and motility of sperm; and in the capacity of testicular antioxidant; Improved histomorphology of testis; Significant decrease of dead and abnormal sperm, the serum level of LH and FSH, the serum activity of lactate dehydrogenase (LDH), creatine phosphokinase (CPK) and glutamic oxaloacetate transaminase (SGOT).	(35)
<i>Punica granatum</i>	28 days 4 groups (n=6)	Male rats	Ethanol extract	15 mg/kg; Twice week; Oral	100 mg/kg; Oral	Significant increase in the sperm count, motility and normality, in the serum level of testosterone and in the total protein of testis tissue; Significant decrease in the testicular level of MDA, in the activity of SOD in the testis, in the testicular level of glutathione.	(36)
<i>Ginkgo biloba</i>	28 days; 4 groups (n=not mention)	Male mice	Extract	6.5 mg/kg; Oral	100 mg/kg; Oral	Improved histomorphology of testis; Significant increase in the sperm count, in the level of testosterone and LH, and in the testicular level of catalase; Significant decrease in the abnormality of sperm, and in the testicular level of MDA.	(37)
<i>Cucurbita pepo</i> var. <i>styriaca</i>	42 days; 4 groups (n=10)	Male rats	Extract	100 mg/kg; Single dose; Intraperitoneal injection	300 and 600 mg/ kg; Intraperitoneal injection	Significant increase in the epididymal sperm count, motility, viability and normality; Improved histomorphology of epididymis.	(38)

Table 1. Continued

<i>Astragalus membranaceus</i>	35 days; 5 groups (n=8)	Male mice	Extract of root	100 mg/kg; Once week; Intraperitoneal injection	100, 500 and 1000 mg/kg; 5 days in each week; Oral	Significant increase in the weight of testis, in the sperm count, in the motility of sperm, and in the cAMP-responsive element modulator (<i>CREM</i>) gene expression.	(39)
<i>Zingiber officinale</i>	42 days; 4 groups (n=10)	Male rats	Extract	100 mg/kg; Single dose; Intraperitoneal injection	300 and 600 mg/kg; Oral	Improved histomorphology of the testis; Significant increase in the count of germ cells and sertoli cell, and in the serum level of antioxidant.	(40)
<i>Trigonella foenum graecum</i>	56 days; 4 groups (n=20)	Male mice	Seed extract	7 mg/kg; 3 times/week; Oral	0.4 g/kg; 3 times/week (same time); Oral	Improved histomorphology of the testes; Significant increase in the serum activity of SOD and catalase; Significant decrease in the serum level of MDA.	(41)
<i>Foeniculum vulgare</i>	3 days; 5 group; (n=5)	Male mice	Essential oil	40 mg/kg; Single dose; Intraperitoneal injection	1 and 2 ml/kg; Oral	Significant decrease in the total sperm abnormality.	(42)
<i>Satureja khuzestanica</i>	28 days; 4 groups (n=8)	Male rats	Essential oil	6 mg/kg; Oral	255 mg/kg; Oral	Significant reduction in the testes lipid peroxidation; Significant increase in the testis total antioxidant power (TAP), in the fertility, in the testosterone level, in the weight of testis, epididymis, Ventral prostate and Vesicule seminal, and in the count and motility of sperm; Significant improvement in the histological index.	(43)
Gallic acid	14 days; 6 groups (n=10)	Male rats	Gallic acid	200 mg/kg; Single dose; Intraperitoneal injection	60 and 120 mg/kg; Oral	Improved histomorphology of the testes and epididymis; Significant increase in the sperm motility and viability, in the serum level of testosterone, LH and FSH, in the weight of epididymis, in the SOD activity of testes, in the SOD activity of epididymis, in the catalase activity of testes, in the glutathione S-transferase activity of testes and epididymis, and in the nitrite level of testes and epididymis; Significant decrease in the H ₂ O ₂ level of testes and epididymis, in the MDA level of testes and epididymis.	(44)
Rutin	28 days; 3 groups (n=5)	Male rats	Rutin	15 mg/kg; twice week; Oral	30 mg/kg; twice week; Oral	Improved morphology of the sperm; Significant decrease in the activity of superoxide dismutase, in the MDA level in epididymis, in the Lactate dehydrogenase (LDH) level in testis and epididymis, and in the Sorbitol dehydrogenase (SDH) level in testis, in sperm count and motility; Significant increase in the activity of catalase in testis and epididymis, in the levels of glutathione, glutathione peroxidase, glutathione reductase and glutathione s-transferase in epididymis, in the alkaline phosphatase (ALP) level in testis, in the acid phosphatase (ACP) level in testis, and in the 3β-Hydroxysteroid dehydrogenase (3β-HSD) and 17β-Hydroxysteroid dehydrogenase (17β-HSD) level in testis.	(45)
Flavonoids of epimedium	35 days; 4 group (n=10)	Male mice	Flavonoids	50 mg/kg; First 7 days; Intraperitoneal injection	200 and 400 mg/kg; 28 days; Oral	Significant increase in the sperm count and motility, in the <i>Bcl-2</i> gene expression, and in the testicular level of SOD and glutathione peroxidase; Significant decrease in the testicular level of MDA, in the testicular germ cell apoptotic index, and in the <i>Bax</i> gene expression.	(46)
Yukmijihwang-tang	56 days; 3 groups (n=7)	Male rats	32% <i>Rehmannia glutinosa</i> , 16% <i>Dioscorea japonica</i> , 16% <i>Cornus officinali</i> , 12% <i>Poria cocos</i> , 12% <i>Paeonia suffruticosa</i> , and 12% <i>Alisma plantago-aquatica</i>	20 mg/kg; First week; Oral	1 g/kg; Oral	Significant increase in the weight of testes, in the <i>CREM</i> gene expression, and in the sperm count and motility; Significant decrease in the testes level of MDA.	(47)
Yangjing capsule	37 days; 4 group (n=9)	Male mice	A mix of plant extracts	50 mg/kg; First 7 days; Intraperitoneal injection	360 and 1260 mg/kg; 30 days; Oral	Significant increase in the sperm count and motility, and in the relative protein expression AR/GAPDH; Significant decrease in the testicular apoptotic index, in the relative protein expression Bax/Bcl-2, and in the relative mRNA expression Bax/Bcl-2.	(48)

Male infertility causes high levels of stress for couples. Defects in spermatogenesis is the most common cause of male infertility (49). CP has been demonstrated to induce testicular toxicity and to degenerate spermatogenesis Sertoli cells. In addition, CP was shown to inhibit the production of androgens in adult male mice. CP seems to cause inhibition of Leydig cells through LH release, which causes a decline in production of testosterone and hence makes spermatogenesis defective (50). Decreased proportion of sperm is due to increased amount of oxygen free radicals (51). This can be attributed to the oxygen free radicals produced by CP (52), because CP can cause oxidative stress in addition to enzymatic and hormonal alterations (53).

Antioxidants are able to inhibit oxygen free radicals, reduce oxidative stress, and minimize associated complications (54-58). The plants and plant-based compounds, presented in this review article, are highly useful to reduce oxidative stress. Moreover, this review demonstrated CP-induced escalation of oxidative stress indices and CP's effect on reproductive system toxicity. All the reviewed studies indicated that phytotherapy caused attenuation of oxidative stress. All of the plants offered in this article have certain compounds such as flavonoids. Flavonoids are phenolic compounds that can be found in many plants and exert antioxidant properties (59).

Conclusion

Plants that contain flavonoids can reduce CP-induced toxicity, which causes oxidative stress and increases free radicals in testicular tissue, and therefore exert their protective effects on the drugs' side effects.

Authors' contribution

MAA, MAS, and EL have searched the literature and written the draft. SH, RS, and TL have edited the manuscript. All authors have read and approved the final version.

Conflicts of interest

Authors declare that they have no conflict of interest.

Ethical considerations

Ethical issues (including plagiarism, data fabrication, double publication) have been completely observed by the authors.

Funding/Support

This research received no specific grant from any funding agency in the public, commercial, or not-for-profit sectors.

References

1. Lawson M, Vasilaras A, De Vries A, Mactaggart P, Nicol D. Urological implications of cyclophosphamide and ifosfamide. *Scand J Urol Nephrol.* 2008;42:309-17. doi: 10.1080/00365590701570953.
2. Tripathi DN, Jena GB. Intervention of astaxanthin against cyclophosphamide-induced oxidative stress and DNA damage: a study in mice. *Chem Biol Interact.* 2009;180:398-406. doi: 10.1016/j.cbi.2009.03.017.
3. Viaud S, Saccheri F, Mignot G, Yamazaki T, Daillere R, Hannani D, et al. The intestinal microbiota modulates the anticancer immune effects of cyclophosphamide. *Science.* 2013;342:971-6. doi: 10.1126/science.1240537.
4. Ghiringhelli F, Larmonier N, Schmitt E, Parcellier A, Cathelin D, Garrido C, et al. CD4+CD25+ regulatory T cells suppress tumor immunity but are sensitive to cyclophosphamide which allows immunotherapy of established tumors to be curative. *Eur J Immunol.* 2004;34:336-44. doi:10.1002/eji.200324181
5. Schiavoni G, Sistigu A, Valentini M, Mattei F, Sestili P, Spadaro F, et al. Cyclophosphamide synergizes with type I interferons through systemic dendritic cell reactivation and induction of immunogenic tumor apoptosis. *Cancer Res.* 2011;71:768-78. doi: 10.1158/0008-5472.CAN-10-2788.
6. Kehrer JP, Biswal SS. The molecular effects of acrolein. *Toxicol Sci.* 2000;57:6-15.
7. Ren S, Yang JS, Kalthorn TF, Slattery JT. Oxidation of cyclophosphamide to 4-hydroxycyclophosphamide and deschloroethylcyclophosphamide in human liver microsomes. *Cancer Res.* 1997;57(19):4229-35.
8. Korkmaz A, Topal T, Oter S. Pathophysiological aspects of cyclophosphamide and ifosfamide induced hemorrhagic cystitis; implication of reactive oxygen and nitrogen species as well as PARP activation. *Cell Biol Toxicol.* 2007;23:303-12. doi: 10.1007/s10565-006-0078-0.
9. Abraham P, Rabi S, Selvakumar D. Protective effect of aminoguanidine against oxidative stress and bladder injury in cyclophosphamide-induced hemorrhagic cystitis in rat. *Cell Biochem Funct.* 2009;27:56-62. doi: 10.1002/cbf.1534.
10. Dantas AC, Batista-Junior FF, Macedo LF, Mendes MN, Azevedo IM, Medeiros AC. Protective effect of simvastatin in the cyclophosphamide-induced hemorrhagic cystitis in rats. *Acta cirurgica brasileira/Sociedade Brasileira para Desenvolvimento Pesquisa em Cirurgia.* 2010;25:43-6.
11. Kenney LB, Laufer MR, Grant FD, Grier H, Diller L. High risk of infertility and long term gonadal damage in males treated with high dose cyclophosphamide for sarcoma during childhood. *Cancer.* 2001;91:613-21.
12. Robaire B, Hales B. Paternally mediated effects on development. In: Hood RD, ed. *Developmental and Reproductive Toxicology: A Practical Approach.* Informa Healthcare; 2005:125-45. doi:10.1201/9781420040548.ch5.
13. Sotomayor RE, Segal GA, Cumming RB. Unscheduled DNA synthesis in spermatogenic cells of mice treated in vivo with the indirect alkylating agents cyclophosphamide and mitomen. *Mutat Res.* 1978;50:229-40.
14. Asadi-Samani M, Kooti W, Aslani E, Shirzad H. A systematic review of Iran's medicinal plants with anticancer effects. *J Evid Based Complementary Altern Med.* 2016;21:143-53. doi: 10.1177/2156587215600873.
15. Asadi-Samani M, Rafieian-Kopaei M, Azimi N. Gundelia: a systematic review of medicinal and molecular perspective. *Pak J Biol Sci.* 2013;16:1238-47.
16. Kooti W, Hasanzadeh-Noohi Z, Sharafi-Ahvazi N, Asadi-Samani M, Ashtary-Larky D. Phytochemistry, pharmacology, and therapeutic uses of black seed (*Nigella sativa*). *Chin J Nat Med.* 2016;14:732-45. doi: 10.1016/S1875-5364(16)30088-7.
17. Mahmoudian Sani M, Asadi-Samani M, Rouhi-Boroujeni H, Banitalebi-Dehkordi M. Phytopharmacology and

- phytotherapy of regulatory T cells: A new approach to treat multiple sclerosis. *Der Pharm Lett.* 2016;8:215-20.
18. Parsaei P, Bahmani M, Naghdi N, Asadi-Samani M, Rafieian-Kopaei M, Boroujeni S. Shigellosis phytotherapy: A review of the most important native medicinal plants in Iran effective on *Shigella*. *Der Pharm Lett.* 2016;8:249-55.
 19. Parsaei P, Bahmani M, Naghdi N, Asadi-Samani M, Rafieian-Kopaei M. The most important medicinal plants effective on constipation by the ethnobotanical documents in Iran: A review. *der Pharm Lett.* 2016;8:188-94.
 20. Baharvand-Ahmadi B, Bahmani M, Tajeddini P, Naghdi N, Rafieian-Kopaei M. An ethno-medicinal study of medicinal plants used for the treatment of diabetes. *J Nephropathol.* 2016;5:44-50. doi: 10.15171/jnp.2016.08.
 21. Asadi-Samani M, Bahmani M, Rafieian-Kopaei M. The chemical composition, botanical characteristic and biological activities of *Borago officinalis*: a review. *Asian Pac J Trop Med.* 2014;7S1:S22-8. doi: 10.1016/S1995-7645(14)60199-1.
 22. Samarghandian S, Asadi-Samani M, Farkhondeh T, Bahmani M. Assessment the effect of saffron ethanolic extract (*Crocus sativus* L.) on oxidative damages in aged male rat liver. *Der Pharm Lett.* 2016;8:283-90.
 23. Chinedu E, Arome D, Jacob D. Preliminary assessment of the antiproliferative potential of *Ananas comosus* (pineapple) fruit juice. *J Herbmmed Pharmacol.* 2016;5:50-3.
 24. Raeisi E, Shahbazi-Gahrouei D, Heidarian E. Pineapple extract as an efficient anticancer agent in treating human cancer cells. *Front Cancers.* 2016;1:e03.
 25. Azadmehr A, Hajiaghah R, Afshari A, Amirghofran Z, Refieian-Kopaei M, yousofi Darani H, et al. Evaluation of in vivo immune response activity and in vitro anti-cancer effect by *Scrophularia megalantha*. *J Med Plants Res.* 2011;5:2365-8.
 26. Saffari-Chaleshtori J, Heidari-Soreshjani E, Asadi-Samani M. Computational study of quercetin effect on pre-apoptotic factors of Bad, Bak and Bim. *J Herbmmed Pharmacol.* 2016;5:61-6.
 27. Akram H, Ghaderi Pakdel F, Ahmadi A, Zare S. Beneficial effects of american ginseng on epididymal sperm analyses in cyclophosphamide treated rats. *Cell J.* 2012;14:116-21. PMID: 23508327.
 28. Zanchi MM, Manfredini V, dos Santos Brum D, Vargas LM, Spiazzi CC, Soares MB, et al. Green tea infusion improves cyclophosphamide-induced damage on male mice reproductive system. *Toxicol Rep.* 2015;2:252-60. doi: 10.1016/j.toxrep.2014.12.016.
 29. Mohamadi F, Nikzad H, Taherian A, Taghizadeh M, Azami-Tameh A, Naderian H, et al. Combined effect of ginger and pumpkin seed extracts on rat testis and serum biochemical parameters after cyclophosphamide treatment. *Anat Sci J.* 2014;11:33-40.
 30. Ghaffarie T, Johari H, Najafian M, Kargar H. Effect of hydroalcoholic extract of cinnamon on the pituitary-gonadal axis in adult male rats under chemotherapy by cyclophosphamide. *Zahedan J Res Med Sci.* 2014;16:16-20.
 31. Shalizar Jalali A, Hassanzadeh S, Malekinejad H. Chemoprotective effect of *Crataegus monogyna* aqueous extract against cyclophosphamide-induced reproductive toxicity. *Vet Res Forum.* 2012;2:266-73.
 32. Ch S, Devi KR. Antigenotoxic effects of *Aegle marmelos* fruit extract in cyclophosphamide induced chromosomal aberrations and aberrant sperms in germ cells of Swiss Albino Mice. *Int J Pure Appl Biosci.* 2015;3:178-83. doi: 10.18782/2320-7051.2119.
 33. Singh S, Lata S, Tiwari KN. Antioxidant potential of *Phyllanthus fraternus* Webster on cyclophosphamide induced changes in sperm characteristics and testicular oxidative damage in mice. *Indian J Exp Biol.* 2015;53:647-56.
 34. Shalizar Jalali A, Hasanzadeh S, Malekinejad H. Beneficial effects of *Achillea millefolium* aqueous extract against cyclophosphamide-induced reproductive toxicity. *J Exp Integr Med.* 2013;3:113-9. doi:10.5455/jeim.110313.or.061.
 35. Shalizar Jalali A, Hasanzadeh S, Malekinejad H. *Achillea millefolium* inflorescence aqueous extract ameliorates cyclophosphamide-induced toxicity in rat testis: stereological evidences. *Chin J Nat Med.* 2012;10:247-54. doi: 10.1016/S1875-5364(12)60050-8.
 36. Bhargavan D, Shetty H, Krishna A. Ameliorative effect of punic granatum ethanolic extract in cyclophosphamide induced testicular toxicity in male Wistar rats. *Int J Appl Biol Pharm Technol.* 2015;6(3):229-36.
 37. Sakr S, Mahran H, Abo-El-Yazid S. Effect of Ginkgo biloba extract on cyclophosphamide-induced reproductive toxicity and oxidative stress in male albino mice. *World J Pharm Sci.* 2015;3:16-25.
 38. Aghaei S, Nikzad H, Taghizadeh M, Tameh AA, Taherian A, Moravveji A. Protective effect of pumpkin seed extract on sperm characteristics, biochemical parameters and epididymal histology in adult male rats treated with cyclophosphamide. *Andrologia.* 2014;46:927-35. doi: 10.1111/and.12175.
 39. Kim W, Kim SH, Park SK, Chang MS. *Astragalus membranaceus* ameliorates reproductive toxicity induced by cyclophosphamide in male mice. *Phytother Res.* 2012;26:1418-21. doi: 10.1002/ptr.4756.
 40. Mohammedi F, Nikzad H, Taghizadeh M, Taherian A, Azami-Tameh A, Hosseini SM, et al. Protective effect of *Zingiber officinale* extract on rat testis after cyclophosphamide treatment. *Andrologia.* 2014;46:680-6. doi: 10.1111/and.12135.
 41. Sakr SA, Mahran HA, Abo-El-Yazid SM. Effect of fenugreek seeds extract on cyclophosphamide-induced histomorphometrical, ultrastructural and biochemical changes in testes of albino mice. *Toxicol Ind health.* 2012; 28:276-88. doi: 10.1177/0748233711412427.
 42. Tripathi P, Tripathi R, Patel RK, Pancholi SS. Investigation of antimutagenic potential of *Foeniculum vulgare* essential oil on cyclophosphamide induced genotoxicity and oxidative stress in mice. *Drug Chem Toxicol.* 2013;36:35-41. doi: 10.3109/01480545.2011.648328.
 43. Rezvanfar M, Sadrkhanlou R, Ahmadi A, Shojaei-Sadee H, Rezvanfar M, Mohammadirad A, et al. Protection of cyclophosphamide-induced toxicity in reproductive tract histology, sperm characteristics, and DNA damage by an herbal source; evidence for role of free-radical toxic stress. *Human Exp Tsoxicol.* 2008;27:901-10. doi: 10.1177/0960327108102046.
 44. Oyagbemi AA, Omobowale TO, Saba AB, Adedara IA, Olowu ER, Akinrinde AS, et al. Gallic acid protects against cyclophosphamide-induced toxicity in testis and epididymis of rats. *Andrologia.* 2016;48:393-401. doi: 10.1111/and.12459.
 45. Abarikwu SO, Otuechere CA, Ekor M, Monwuba K, Osobu D. Rutin Ameliorates Cyclophosphamide-induced

- Reproductive Toxicity in Male Rats. *Toxicol Int.* 2012;19:207-14. doi: 10.4103/0971-6580.97224.
46. Yuan D, Wang H, He H, Jia L, He Y, Wang T, et al. Protective effects of total flavonoids from *Epimedium* on the male mouse reproductive system against cyclophosphamide-induced oxidative injury by up-regulating the expressions of SOD3 and GPX1. *Phytother Res.* 2014;28:88-97. doi: 10.1002/ptr.4956.
 47. Oh MS, Chang MS, Park W, Kim DR, Bae H, Huh Y, et al. Yukmijihwang-tang protects against cyclophosphamide-induced reproductive toxicity. *Reprod Toxicol.* 2007;24:365-70. doi: 10.1016/j.reprotox.2007.05.007.
 48. Zhao H, Jin B, Zhang X, Cui Y, Sun D, Gao C, et al. Yangjing Capsule Ameliorates Spermatogenesis in Male Mice Exposed to Cyclophosphamide. *Evid Based Complement Alternat Med.* 2015;2015:980583. doi: 10.1155/2015/980583.
 49. Anawalt BD. Approach to male infertility and induction of spermatogenesis. *J Clin Endocrinol Metab.* 2013;98:3532-42. doi: 10.1210/jc.2012-2400.
 50. Ayala A, Munoz MF, Arguelles S. Lipid peroxidation: production, metabolism, and signaling mechanisms of malondialdehyde and 4-hydroxy-2-nonenal. *Oxid Med Cell Longev.* 2014;2014:360438. doi: 10.1155/2014/360438.
 51. Lui RC, Laregina MC, Herbold DR, Johnson FE. Testicular cytotoxicity of intravenous doxorubicin in rats. *J Urol.* 1986;136:940-3.
 52. Selvakumar E, Prahalthan C, Mythili Y, Varalakshmi P. Beneficial effects of DL-alpha-lipoic acid on cyclophosphamide-induced oxidative stress in mitochondrial fractions of rat testis. *Chem Biol Interact.* 2005;152:59-66. doi: 10.1016/j.cbi.2005.01.009.
 53. Selvakumar E, Prahalthan C, Mythili Y, Varalakshmi P. Protective effect of DL-alpha-lipoic acid in cyclophosphamide induced oxidative injury in rat testis. *Reprod Toxicol.* 2004;19:163-7. doi: 10.1016/j.reprotox.2004.06.015.
 54. Ghatreh-Samani M, Esmaeili N, Soleimani M, Asadi-Samani M, Ghatreh-Samani K, Shirzad H. Oxidative stress and age-related changes in T cells: is thalassemia a model of accelerated immune system aging? *Cent Eur J Immunol.* 2016;41:116-24. doi: 10.5114/ceji.2015.56973.
 55. Rafieian-Kopaei M, Baradaran A, Rafieian M. Plants antioxidants: from laboratory to clinic. *J Nephropathol.* 2013;2:152-3. doi: 10.12860/JNP.2013.26.
 56. Hajian S. Positive effect of antioxidants on immune system. *Immunopathol Persa.* 2015;1:e02.
 57. Shirzad H, Taji F, Rafieian-Kopaei M. Correlation between antioxidant activity of garlic extracts and WEHI-164 fibrosarcoma tumor growth in BALB/c mice. *J Med Food.* 2011;14:969-74. doi:10.1089/jmf.2011.1594.
 58. Baradaran A. Herbal antioxidant to ameliorate vascular biology. *Angiol Persica Acta.* 2017;2:e01.
 59. Pietta PG. Flavonoids as antioxidants. *J Nat Prod.* 2000;63:1035-42.

Copyright © 2017 The Author(s); Published by Nickan Research Institute. This is an open-access article distributed under the terms of the Creative Commons Attribution License (<http://creativecommons.org/licenses/by/4.0>), which permits unrestricted use, distribution, and reproduction in any medium, provided the original work is properly cited.