

CrossMark
click for updates

Unusual presentation of acute kidney injury with tumour lysis syndrome

Mirza Yasar Baig*^{ID}, Rajkumar Chinnadurai^{ID}, Constantina Chrysochou^{ID}

Department of Renal Medicine, Salford Royal NHS Foundation Trust, Salford, UK

ARTICLE INFO

Article Type:
Case Report

Article History:
Received: 10 September 2020
Accepted: 10 November 2020
ePublished: 24 November 2020

Keywords:
Tumour lysis syndrome
Acute kidney injury
Rasburicase

ABSTRACT

Tumour lysis syndrome (TLS) can cause acute kidney injury (AKI) by the breakdown of intracellular contents during treatment for malignancies with large tumour burden. We report a case with an unusual presentation of AKI needing renal replacement therapy. Investigation of the cause for AKI led to the diagnosis of an underlying malignancy (lymphoma). Treatment of a Bell's palsy with steroids before presenting to our service has caused the AKI giving us the overarching diagnosis of TLS in this patient with lymphoma.

Implication for health policy/practice/research/medical education:

This case report highlights the following points:

1. Tumor lysis syndrome should be considered in patients who present with broad spectrum of symptoms and AKI.
2. AKI with high phosphate and low calcium levels should prompt in checking uric acid levels.
3. Burkitt's lymphoma can present as facial nerve palsy.
4. Prednisolone has active lysis effect on lymphoma.

Please cite this paper as: Baig MY, Chinnadurai R, Chrysochou C. Unusual presentation of acute kidney injury with tumour lysis syndrome. J Renal Inj Prev. 2021; 10(2): e16. doi: 10.34172/jrip.2021.16.

Introduction

Tumour lysis syndrome (TLS) is one of the oncological emergencies leading to acute kidney injury (AKI). In malignancies with a high proliferative rate, large tumour burden and high sensitivity to treatment, initiation of cytotoxic therapy, cytolytic antibodies, radiation or sometimes even glucocorticoid treatment can result in lysis of tumour cells. TLS is caused by the rapid release of intracellular contents by lysis of tumour cells. It can lead to hyperuricemia, hyperphosphatemia, hyperkalemia and hypocalcaemia. Deposition of uric acid and calcium phosphate crystals in the renal tubules can result in AKI, which is often exacerbated by concomitant intravascular volume depletion (1,2).

Case Presentation

We present a 56-year-old gentleman who initially presented to his general practitioner (GP) with recurrent headaches and tiredness. He also had left-sided flank

pain associated with cough. He has been suffering from low mood. His GP treated him with analgesics including co-codamol and ibuprofen which he took 3-4 times per day for 4 to 5 days. As his symptoms did not settle, he was prescribed amoxicillin for treating a presumed lower respiratory tract infection.

He then presented himself to the accident and emergency (A&E) department as his symptoms persisted despite completing a course of amoxicillin. He had routine blood tests which were unremarkable. He had a chest-X-ray which showed a patchy consolidation and he was given a seven-day course of doxycycline and discharged back to his GP care.

A week later, he developed sudden onset right-sided facial weakness. He called the ambulance, and an acute stroke pathway was initiated. On examination, he was unable to close the right eye fully, but no change to sensation and there was no upper and lower limb weakness. He was diagnosed with right lower motor neuron facial

*Corresponding author: Mirza Yasar Baig, Email: mirza.baig@srft.nhs.uk

nerve palsy (Bell's palsy) and was started on prednisolone 50mg once a day and discharged home.

Five days later he presented again to A&E with ongoing left sided flank pain, though his cough had improved. He felt more tired and lethargic which was thought likely due to codeine given by his GP. Bloods indicated AKI stage 2 with potassium 5.5 mmol/L, urea 28 mmol/L, creatinine 222 $\mu\text{mol/L}$ (baseline creatinine 104 $\mu\text{mol/L}$), calcium 2.68 mmol/L, phosphate 1.79 mmol/L, alkaline phosphatase 312 U/L and low platelets of $86 \times 10^9/\text{L}$ (normal range of values shown in Table 1). He had a negative haemolytic screen. Urine dip showed trace of blood and protein. The differential diagnosis for AKI at this stage included acute interstitial nephritis or acute tubular injury or renal tract obstruction due to renal stones leading to hydronephrosis.

He then had a series of radiological investigations including ultrasound abdomen, which showed normal-sized kidneys and no other findings. His non-contrast computerised tomography (CT) abdomen (Figure 1) showed fat stranding around the left ureter which may be secondary to a recently passed stone. Additionally, it showed an incidental finding of a four centimetres left retroperitoneal mass in the Gerota's fascia (a fibrous connective tissue that covers the kidneys and the adrenal glands). The mass had a non-specific appearance, and the differential diagnosis included solid organ malignancy or lymphadenopathy or a carcinoid tumour.

Clinically, he had ongoing flank discomfort and now had side effects of steroids, including high blood glucose levels, erosive gastritis. He was commenced on proton pump inhibitors. He subsequently developed neurological symptoms, including headache, agitation, drowsiness, and double vision. Examination revealed a new left sixth cranial nerve palsy. He had a CT scan followed by magnetic resonance imaging of his brain, which was unremarkable. A lumbar puncture performed for cerebrospinal fluid analysis showed raised protein and white cell counts but no other abnormalities. He was reviewed by a neurologist, who suggested a differential diagnosis of either malignancy with meningeal infiltration or vasculitis. All the soluble immunology (vasculitis screen) was negative, and he continued the steroids for the Bell's facial palsy. His blood pressure increased significantly and remained persistently high with an average systolic blood pressure of 180 mm Hg despite antihypertensive medications

Table 1. Normal range for the biochemical variables

Variable	Normal range	Units
Potassium	3.5-5.3	mmol/L
Corrected calcium	2.20 -2.60	mmol/L
Phosphate	0.80-1.50	mmol/L
Uric acid	200-430	$\mu\text{mol/L}$
Creatinine	62-115	$\mu\text{mol/L}$
Urea	2.5-7.8	mmol/L

and needing intravenous labetalol in high dependency initially. The gastroenterology team reviewed him as he had an episode of meleana and drop in haemoglobin. His esophagogastroduodenoscopy showed oesophagitis and erosive gastritis. The gastroenterologist raised suspicion of a neuroendocrine tumour.

His renal function deteriorated further with a creatinine of 445 $\mu\text{mol/L}$, urea of 38 mmol/L and potassium of 6.4 mmol/L. A temporary dialysis catheter was inserted, and dialysis was initiated. He required 16 dialysis sessions in total. Kidney biopsy was considered by nephrology team but could not proceed as patient was not clinically stable to have invasive intervention. He had a repeat CT thorax, abdomen and pelvis which showed liver cirrhosis along with small lymph nodes in the pancreas but no change in the known four centimetre left mesenteric mass with a differential diagnosis of a neuroendocrine tumour or lymphoma. The location of the mass was not amenable to biopsy.

Hematologists were involved in his care. A leucoerythroblastic blood film sample was sent for flow cytometry, and initial testing showed a mature B cell clone compatible with high-grade lymphoma. All the above led to a final diagnosis of Burkitt's lymphoma with central nervous system disease involving the right seventh and left sixth cranial nerve which was confirmed with cytogenetic testing of bone marrow specimen. A raised uric acid level 1600 $\mu\text{mol/L}$ (normal 200–430 $\mu\text{mol/L}$), and phosphate 5 mmol/L gave the overarching diagnosis of TLS as the cause for AKI. TLS was probably precipitated by the steroid treatment for Bell's palsy. The trend of serum creatinine and serum phosphate is shown in Figures 2A and 2B respectively.

Differential diagnosis for AKI in this case report

Acute tubular necrosis
Acute interstitial nephritis
Paraneoplastic glomerulonephritis
Tumour lysis syndrome

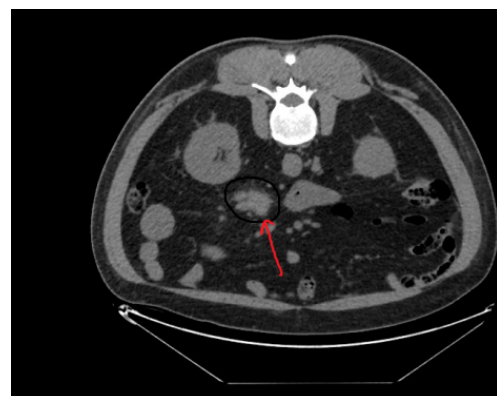

Figure 1. Non-contrast computerised tomography abdomen showing a left retroperitoneal mass in the Gerota's fascia.

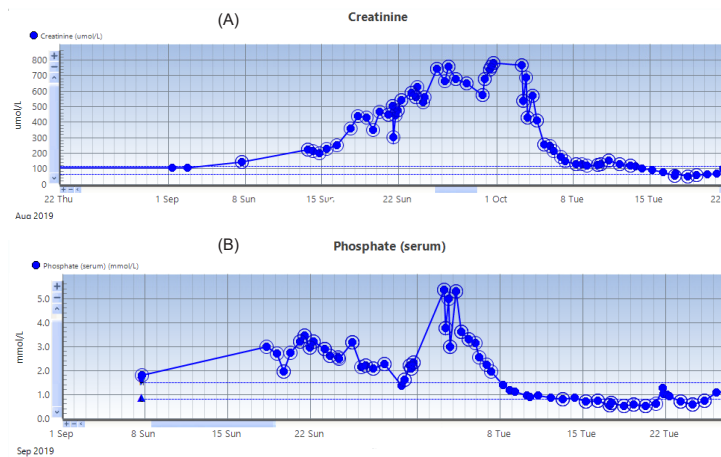


Figure 2. Trend of serum (A) creatinine and (B) phosphate.

Treatment

The patient was commenced on R-CHOP (rituximab, cyclophosphamide, doxorubicin, vincristine and prednisolone) chemotherapy, intrathecal methotrexate and rasburicase. He was also started on a trial regime of R-CODOXM/R-IVAC with twice-weekly intrathecal chemotherapy.

Outcome and follow up

After initiation of chemotherapy and rasburicase his renal function recovered to baseline and he did come off dialysis eventually. No evidence of active Burkitt's lymphoma was seen post-chemotherapy.

Discussion

TLS can be fatal if not recognised early as this can lead to cardiac dysfunction and multi-organ failure due to the severe biochemical disturbances. In-addition to chemotherapy, other triggering factors include corticosteroid therapy, radiotherapy, anaesthesia, and pyrexia (3). Although it can occur spontaneously, TLS is often associated with rapid cell breakdown after initiation of chemotherapy and the consequent massive release of intracellular contents that overwhelm the body's homeostatic and excretory mechanisms (4).

AKI associated with TLS has been considered to be exclusively a crystal-dependent process caused by the massive and abrupt release of intracellular metabolites from chemo sensitive, rapidly proliferating tumour cells that undergo rapid lysis and release nucleic acid

breakdown products, phosphorus and potassium. Both urate and calcium phosphate crystals may cause crystal-dependent injury of the kidney, which overwhelms the normal homeostatic mechanisms auto regulating normal renal physiology (5).

There is no uniform classification for TLS, but the most used one is the Cairo–Bishop classification which includes laboratory and clinical criteria (Table 2). Clinical criteria include renal, cardiac or neurologic dysfunction. These manifestations are supposed to occur within 3–7 days of chemotherapy, and two markers should be abnormal within 24 hours (6).

Delivery of crystalloid intravenous fluids is recommended for all patients and is essential to those with higher risk of TLS. Volume expansion supports adequate intravascular volume and renal blood flow, which maintain glomerular filtration (7). Urinary alkalinisation is not recommended in the management of TLS due to exacerbation of hypocalcaemia (8). Rasburicase is an aspergillus-derived recombinant urate oxidase approved by the US Food and Drug Administration (FDA) in 2002 for the initial management of hyperuricemia in paediatric patients with leukaemia, lymphoma, and solid tumour malignancies receiving anticancer therapy. It was subsequently approved for use in adults in 2009. Rasburicase catalyses the conversion of uric acid to allantoin, carbon dioxide, and hydrogen peroxide (9).

The need for renal replacement has significantly reduced since the advent of rasburicase, but during induction therapies around 1.5% of children and 5% of adults are

Table 2. Cairo–Bishop classification of TLS (6)

Laboratory TLS		Clinical TLS
Uric acid	>8.0 mg/dL (>475 umol/L (25% rise)	Acute kidney injury
Potassium	>6.0 mEq/dL (25% rise)	Cardiac arrhythmia
Phosphorus	>4.6 mg/dL (>1.48 mmol/L) (25% rise)	Seizure, tetany
Calcium	<7.0 mg/dL (<1.68 mmol/L) (25% decrease)	Seizure, tetany or other symptomatic hypocalcaemia

Abbreviation: TLS, tumour lysis syndrome.

noted to require dialysis. Due to the rapid onset of clinical manifestations in TLS, RRT may need to be initiated earlier unlike other causes of AKI (10).

In this case report, we present a challenging case of AKI with unusual presentation. Multiple speciality (renal medicine, gastroenterology, neurology, and haematology) input was needed in the management of this complex case. He had several invasive and non-invasive investigations before a diagnosis can be reached.

Conclusion

To summarise, we present the case of 56-year-old male who presented with non-specific malaise, left flank pain, cough and a Bell's palsy for which he received steroids. Subsequent blood tests indicated AKI requiring dialysis. Further investigations diagnosed Burkitt's lymphoma, which was sensitive to prednisolone and led to TLS evident by hyperuricemia, hyperkalemia and hyperphosphatemia. Renal function and uric acid levels came back to normal after the treatment of TLS with rasburicase.

Authors' contribution

All the authors were involved in conception, drafting/ revising the article and final approval of the version to be published. MYB, RC and CC, read and signed the final manuscript.

Conflicts of interest

The authors declare that they have no competing interests.

Ethical considerations

Ethical issues (including plagiarism, data fabrication, double publication) have been completely observed by authors. An informed written consent has been obtained from the patient.

Funding/Support

None.

References

1. Weeks AC, Kimple ME. Spontaneous tumor lysis syndrome: A case report and critical evaluation of current diagnostic criteria and optimal treatment regimens. *J Investig Med High Impact Case Reports*. 2015;3(3). doi: 10.1177/2324709615603199.
2. Malaguarnera G, Giordano M, Malaguarnera M. Rasburicase for the treatment of tumor lysis in hematological malignancies. *Expert Rev Hematol*. 2012;5:27-38. doi: 10.1586/ehm.11.73.
3. Chubb EA, Maloney D, Farley-Hills E. Tumour lysis syndrome: An unusual presentation. *Anaesthesia*. 2010;65:1031-3.
4. Cairo MS, Bishop M. Tumour lysis syndrome: New therapeutic strategies and classification. *Br J Haematol*. 2004;127:3-11.
5. Shimada M, Johnson RJ, May WS, Lingegowda V, Sood P, Nakagawa T, et al. A novel role for uric acid in acute kidney injury associated with tumour lysis syndrome. *Nephrol Dial Transplant*. 2009;24:2960-4.
6. Ali A, Al-Janabi RD. A rare cause of tumour lysis syndrome and acute kidney injury. *J R Coll Physicians Edinb*. 2020;50:35-38. doi: 10.4997/JRCPE.2020.109.
7. Howard SC, Jones DP, Pui CH. The tumor lysis syndrome. *N Engl J Med*. 2011;364:1844-54. doi: 10.1056/NEJMra0904569.
8. Wilson FP, Berns JS. Tumor lysis syndrome: new challenges and recent advances. *Adv Chronic Kidney Dis*. 2014;21:18-26. doi: 10.1053/j.ackd.2013.07.001.
9. Dinnel J, Moore BL, Skiver BM, Bose P. Rasburicase in the management of tumor lysis: An evidence-based review of its place in therapy. *Core Evidence*. 2015;10:23-38. doi: 10.2147/CE.S54995.
10. Jeha S, Kantarjian H, Irwin D, Shen V, Shenoy S, Blaney S, et al. Efficacy and safety of rasburicase, a recombinant urate oxidase (Elitek™), in the management of malignancy-associated hyperuricemia in pediatric and adult patients: Final results of a multicenter compassionate use trial. *Leukemia*. 2005;19(1):34-8.

Copyright © 2021 The Author(s); Published by Nickan Research Institute. This is an open-access article distributed under the terms of the Creative Commons Attribution License (<http://creativecommons.org/licenses/by/4.0>), which permits unrestricted use, distribution, and reproduction in any medium, provided the original work is properly cited.