

CrossMark  
click for updates

## Effect of hypericum perforatum tea on renal histology and function

Adil A. Mustafa<sup>1</sup> , Moamin J. Salim<sup>2</sup>, Khalaf N. Ahmad<sup>1</sup>, Mohammed F. Ahmed<sup>2</sup>, Azzawi M. Hadi<sup>2\*</sup> <sup>1</sup>Department of Food Sciences, Tikrit University, College Agriculture, Tikrit, Iraq<sup>2</sup>Department of Surgery, University of Ninevah, College of Medicine, Mosul, Iraq

### ARTICLE INFO

**Article Type:**  
Short Communication**Article History:**  
Received: 1 August 2021  
Accepted: 20 November 2021  
Published online: 6 December 2021**Keywords:**  
*Hypericum perforatum*  
Renal function  
Serum creatinine  
Kidney failure

### ABSTRACT

**Introduction:** *Hypericum perforatum* consists of several biologically active compounds that may affect cell physiology.**Objectives:** This study attempted to estimate the effect and safety of a tea that was prepared from *H. perforatum* on renal histology and function.**Materials and Methods:** A double-blind controlled experimental trial was conducted on 25 male rats. These animals were divided into four groups. Three of them were labeled as the study groups, and each consisted of seven animals. The fourth group was labeled as the control group consisting of four animals that lived in the same environment and consumed the same food as the other groups. The animals in each study group consumed a prepared tea with a different concentration for each group. The herbal tea of *H. perforatum* was made as recommended by the local traditional preparation method. Doses of 3, 6, and 9 cc/kg/d were calculated and selected according to the recommendation. Each of these doses was given to each group of the experiment for four weeks mixed with water.**Results:** A slight increase in blood urea and serum creatinine and a decrease in serum albumin levels were noticed in the experimental groups compared to the control group. In addition, the weight of the kidneys in the study groups was more than the control group. There were microscopical changes in the renal histology that was noticed in the higher doses of *H. perforatum* tea.**Conclusion:** Higher doses of *H. perforatum* tea can induce damage to the renal tissue.

### Implication for health policy/practice/research/medical education:

In a double-blind controlled experimental trial was conducted on male rats, we found, high doses of hypericum perforatum tea may lead to adverse effects on renal function and histology; however, it could be beneficial at low and moderate doses.

**Please cite this paper as:** Mustafa AA, Salim MJ, Ahmad KN, Ahmed MF, Hadi AM. Effect of hypericum perforatum tea on renal histology and function. J Renal Inj Prev. 2022; 11(2): e31942. doi: 10.34172/jrip.2022.31942.

### Introduction

Plants have had a major role in human health since early medical practice. Early experiments showed noticeable effects of plants in relieving symptoms which encouraged people to use various types of plants as medications (1). Some herbal therapists advise diabetic patients to consume *Hypericum perforatum* tea twice daily with the optimism to control blood glucose and lipid levels.*Hypericum perforatum* belongs to the family Hypericaceae, also known as St. John's wort (SJW), which is a home remedy in many Eastern countries (2). The major bioactive compounds such as flavonoids, phloroglucinols, and naphthodianthrones have been reported to relievedepression by influencing the serotonergic pathways. These components also downregulate the cytokines that lead to pro-inflammatory effects (3-6). The hydrophilic extracts of polyphenols potentiate the immune system by activating mononuclear cells which reinforce cellular immunity. Humoral immunity is also activated and increases the production of antibodies against various antigens. In contrast, lipid-soluble polyphenols suppress the immune system (7). In addition, extracts of SJW promote the activity of catalyzing enzymes, especially catalase and superoxide dismutase, which prevent the effect of oxidative stress on tissues (8). *H. perforatum* extracts reduce the levels of malondialdehyde, a marker

\*Corresponding author: Azzawi M. Hadi, Email: azzawihadi@gmail.com

of oxidative stress activity, by increasing catalase and glutathione peroxidase activity. These enzymes protect the cells from harmful oxidative stress effects (9). On the other hand, *H. perforatum* tea may affect renal histology and function which might have already been insulted by diabetic nephropathy.

### Objectives

There is limited information about the nephrotoxicity effects and toxic dosage of *H. perforatum* tea. However, some studies have reported that its nephroprotective effects. This study aims to explore and estimate the level of safety and effect of *H. perforatum* tea consumption on renal histology and function.

### Material and Methods

#### Study design

This experimental study has a double-blinded control design and evaluates the effect of water-soluble extracts of *H. perforatum*, prepared as a tea, on rat renal function and histology. Twenty-five rats were divided into three study groups with seven rats in each that were treated with different concentrations of *H. perforatum* tea. A fourth group consisting of four rats was labeled as the control group and received similar feeding and environmental circumstances as the other groups.

The *H. perforatum* tea was made by mixing 250 g of *H. perforatum* leaves in 4 L of water and was boiled until half of the water evaporated. This method was similar to the traditional preparation for diabetic patients in our region. The prepared tea was proposed to improve the control of diabetes and the lipid profile of those patients. The dose of 250 cc twice a day was used by the patients. We used 6 cc/kg/d for the rats in this study (HP2), since the estimated 3 cc/kg/d was given as the lower dose (HP1) and the 9 cc/kg/d was given as a higher dose (HP3). Each experimental animal group received one of these tea doses as well as an oral water supply for one month. After a month, the animals were harvested for organs and blood according to the protocols. The blood was obtained to measure the levels of blood urea, serum creatinine, and serum albumin. The kidneys were weighed and pathological slides were prepared to detect histological changes. The kidneys of the control and study groups were compared histologically.

#### Data analysis

Statistical analysis was conducted by student's *t* test to compare the results of the functions of both the study and control groups. The *P* value below 0.05 was set as the significance level.

### Results

#### Histology

The histological findings showed increased glomerular injuries and medullary infiltration by lymphoid and

connective tissue cells which may lead to fibrosis and renal atrophy with prolongation of receiving treatment. The degree of renal injury was increased with the increased dose of *H. perforatum*. As shown in Table 1, the renal weight reciprocally increased with the addition of the dose; however, it was not significant except in the group that received the high dose (HP3).

Figure 1 shows the histological examination of the control group. The section shows the cortex of the kidney that contains glomeruli. The glomerulus is formed by a tuft of capillaries with the presence of glomerular epithelium on its surface. Each glomerulus is surrounded by capsule. The capsules are continued as the proximal and then, distal convoluted tubules. The proximal convoluted tubules are lined by pyramidal cells with a narrow lumen, while distal convoluted tubules are lined by simple cuboidal cells with a wide lumen. The medulla of the kidney contains the renal tubules and collecting ducts and between them, there is a thin segment of the loop of Henle. The blood capillaries are present among these tubules in the interstitial connective tissue.

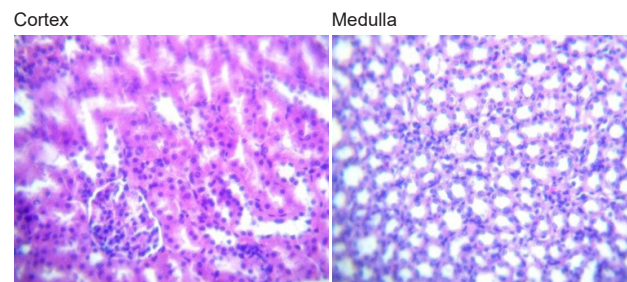
Figure 2 reveals the kidney histology of the first study group (HP1) that received 3cc/kg of *H. perforatum* tea. The glomeruli and tubules seemed normal, but the cortical blood vessels were congested with blood. In addition, the medulla was infiltrated by kidney epithelioid cells and lymphocytes.

Figure 3 represents the kidney histology of the second study group (HP2) that were exposed to 6cc/kg of *H. perforatum* tea. The sections demonstrated some atrophied glomeruli, while others appeared normal; the tubules were normal but there were congested blood vessels. The medullary structures were normal; however, the medulla was invaded by numerous connective tissue cells with many lymphocytes within the interstitium.

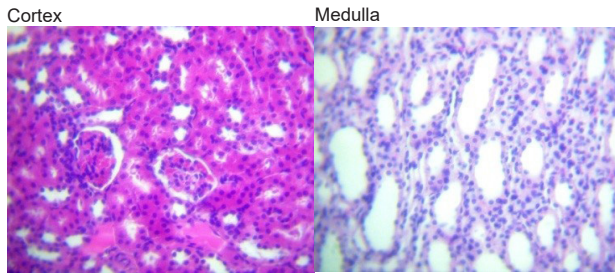
Figure 4 exhibits the kidney histology of the third study

**Table 1.** The renal weight of the control and experimental groups that consumed *H. perforatum* with different concentrations

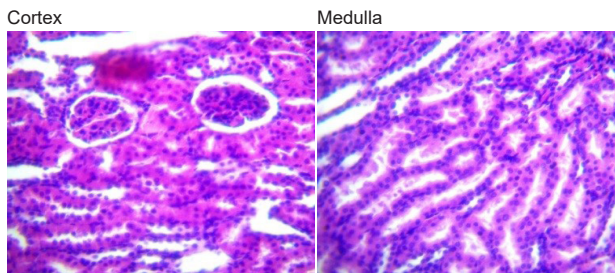
Groups	Kidney weight (g)
Normal control	1.85 ± 0.06
HP 1	2.10 ± 0.06
HP 2	2.14 ± 0.09
HP 3	2.23 ± 0.07*



**Figure 1.** The renal histological examination of the control group.



**Figure 2.** The kidney histology of the first study group (HP1) that were exposed to 3 cc/kg of *H. perforatum* tea.

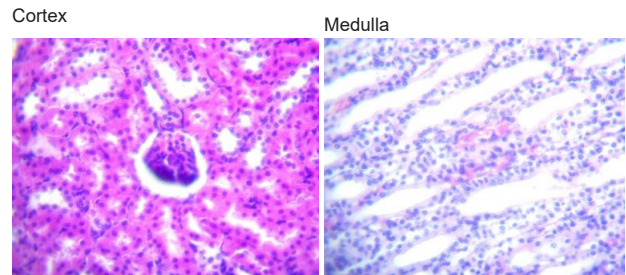


**Figure 3.** The kidney histology of the second study group (HP2) that were exposed to 6 cc/kg of *H. perforatum* tea.

group (HP3) that consumed 9 cc/kg of *H. perforatum* tea. The sections show that most of the glomeruli were atrophied and were demonstrated as condensed masses with lymphocytic diffusion on their surface. These atrophied glomeruli were also displaced to the periphery of the Bowman's capsule. The cortical blood vessels were congested with hemolysed blood. In addition, the proximal convoluted tubules contained few sloughed epithelioid cells and glomerular filtrate. The renal medulla contains normal tubules however, this part is invaded by numerous connective tissue cells and lymphocytes with the presence of congested blood vessels.

### Biochemistry

Table 2 illustrates a progressive deterioration of renal function with increasing doses of *H. perforatum*. The increase in the parameters of renal function, (serum urea and creatinine) is not significant in low and moderate doses (HP1 and HP2). However, it was significant in the group that consumed the high concentration (HP3) compared to the control group. In addition, the serum albumin in the high dose group is significantly lower than



**Figure 4.** The kidney histology of the third study group (HP3) that were exposed to 9 cc/kg of *H. Perforatum* tea.

in the control group. Nevertheless, the decrease is not significant in low and moderate doses (HP1 and HP2).

### Discussion

Since the early times, medical professionals have tried many types of plants and herbs to relieve the suffering of their patients. The relatively lower price, few reported side effects which are supported by promising outcomes in many cases encourages individuals to use them. *H. perforatum* is a good example of a herbal water extract that has been used by patients with diabetes to control glucose and lipid levels in Middle Eastern countries (1). *H. perforatum* has several active components like flavonoids, flavonoid derivatives, hypericin, hyperforin, xanthone derivatives, and biapigenin that have antioxidant activity through different pathways including the scavenging of free radicals, inhibition of lipid peroxidation, and activation of signal transducers (10,11).

Flavonoids are a major component of *H. perforatum*. The intake of flavonoids enhances the function of the cardiovascular system and minimizes the risk of cardiovascular events. This effect is attained through the enhancement of the endothelial integrity and, in turn, function. Consequently, systolic and diastolic arterial blood pressure will reduce (12). Endothelial function with high levels of nitric oxide (NO) has effective bioavailability after flavonoid intake which may explain the improvement of blood flow by the raised endothelial NO level and activity (13), these events can explain the dilated capillaries in serial sections of animal's kidneys in the experiment arm of the study.

The dilation of capillary vessels may also explain the edema that affects the renal parenchyma and the increment of the renal weight. In addition, it may also

**Table 2.** The serum levels of blood urea, creatinine, albumin of the control and experimental groups that consumed *H. perforatum* with different concentrations.

Groups	Serum creatinine (mg/dL)	Blood urea (mg/dL)	Serum albumin (g/dL)
Normal control	0.62 ± 0.09	26.43 ± 1.75	4.68 ± 0.18
HP 1	0.65 ± 0.14	32.98 ± 1.48	4.46 ± 0.14
HP 2	0.83 ± 0.16	36.75 ± 1.54	3.84 ± 0.20
HP 3	1.28 ± 0.08*	46.98 ± 1.58*	3.12 ± 0.17*

\*P < 0.05.

lead to an event similar to the compartment syndrome that leads to atrophy of the glomeruli and tubules and, eventually, causes renal dysfunction.

Flavonoid has an antioxidant activity that protects the cells from reactive oxygen species (ROS) which have damaging effects on cells. These free radicals and ROS are produced by the normal oxygen metabolic pathway. The free radicals also interfere with cell function by a mechanism that is not well understood. One of the key incidents caused by ROS is the peroxidation of lipids which damage the cell membrane by changing the cross-membrane charge. This condition alters ion transfer and eventually, the cross membrane osmotic pressure leads to cellular edema and ultimately, death. Accumulation of free radicals attracts a variety of mediators that moderate the inflammatory response that resulted in tissue injuries and damage (14).

Regular intake of flavonoids with sufficient doses provides the expected protective effect. However, the conjugation pathway, prolonged the half-life of flavonoids to more than a day may lead to the accumulation of flavonoids to a toxic level if the dose increases (15), especially if the flavonoids are taken as a supplement with a high potency formula (16). Since a tested dose of 10 g/kg/daily had no reported genotoxicity in somatic or germ cells flavonoids have been proved to be safe compounds with no significant reported side effects or toxicological events (17).

A study mentioned that the histological and biochemical outcomes favored the use of *H. perforatum* as a cofactor that is protective against acute renal injuries caused by ischemia-reperfusion (I/R). This result was supported by the dilation of renal tubules and the desquamation of the epithelium that were decreased in ischemia-reperfusion conditions in a group that used *H. perforatum* as an adjuvant factor in their study. They compared them with the ischemia-reperfusion group that did not use *H. perforatum* (HP). Their study found that despite this protective effect, the levels of blood urea and serum creatinine were comparable in both study groups; (I/R) and (I/R + HP) (18). In our study, we also reported a significant increase in the indices of renal function with the high dose of *H. perforatum* (HP3).

The renal insult caused by the high dose of *H. perforatum* in our study may not be related to the high dose of flavonoids in *H. perforatum* tea; however, it could be related to synergism with other compositions or may be associated with the toxic materials produced with this preparation method. Heat can lead to oxidation, breakdown, and extraction of the active bio-compounds of vegetables (19). A positive and negative heat effect on the heat-treated food are dependant on the morphology of the vegetables and their nutritional properties (20); therefore, the heating variables (such as duration and degree) cause various effects on the antioxidant properties of food (21). The antioxidant properties may decline with

heating through the destruction of antioxidant materials or by the formation of new pro-oxidant compounds. This situation may cause a deleterious effect on the living cells. The altered structure of the newly formed antioxidants as well as the formation of unique antioxidant compounds may amplify the original antioxidant condition (22,23). Such results indicate that heat may change antioxidant properties in fruits and vegetables. However, a report suggested that the antioxidant profile of many food materials declined if heated to a level between 65-100°C (24).

Some chemical materials can induce oxidative stress on the tissues which are known as pro-oxidants. The induction of oxidative stress by pro-oxidants is either through the production of reactive oxygen species or inhibition of pre-existing antioxidants. Interestingly, some of the well-known antioxidants are reported to have pro-oxidant functions. Some determinant factors can enhance the transformation of antioxidant to pro-oxidant agents. These determinants include the presence of metal ions in the structure of the antioxidant, the level of the antioxidant in the milieu of the tissue matrix, and the oxidation-reduction (redox) potential of the antioxidant in that environment (25). These functional changes in antioxidants may explain the renal damage caused by the high dose of HP3 tea.

### Conclusion

In summary, high doses of *H. perforatum* may lead to adverse effects on renal function and histology; however, it could be beneficial at low and moderate doses.

### Authors' contribution

AAM was the principle investigator of the study. MJS and KNA were involved in the concept and design. MFA and AMH revised the manuscript and critically evaluated the intellectual contents. All authors participated in the preparation of the final draft, revised the manuscript, and critically evaluated the intellectual contents. All authors have read and approved the content of the manuscript and confirmed the accuracy and integrity of all parts of the work.

### Conflicts of interest

We declare that there is no conflict of interest in this study.

### Ethical issues

All of the performed procedures were approved by the Ethical Committee of the Department of Food Sciences, Tikrit University, Tikrit, Iraq, with reference number 73 on 13th April 2020. They were also based on the ethical principles of the International Committees for the Protection of Animal Rights and Laboratory and the National Health and Medical Research Council guidelines. Before the initiation of the study, the protocols of the study including animal care, nutrition, prescribing

method, anesthesia, and euthanasia procedures were checked and approved to agree with the principles of the ethical committee of Tikrit university. Additionally, ethical issues (including plagiarism, data fabrication, double publication) have been completely observed by the authors.

### Funding/Support

The study was self funded by the authors.

### References

- Mustafa AA, Ahmad KN, Abbass YI, Hadi AM. Effects of *Hypericum perforatum* on histology of the testes and sex hormones of male rats. *Sys Rev Pharm* 2020;11:832-835. doi: 10.31838/srp.2020.10.124
- Damlar I, Arpag OF, Tatli U, Altan A. Effect of *Hypericum perforatum* on the healing of xenografts: a histomorphometric study in rabbits. *Br J Oral Maxillofac Surg*. 2017;55:383-7. doi: 10.1016/j.bjoms.2016.12.003.
- Fornal CA, Metzler CW, Mirescu C, Stein SK, Jacobs BL. Effect of standardized extracts of St. John's wort on the single-unit activity of serotonergic dorsal raphe neurons in awake cats: comparisons with fluoxetine and sertraline. *Neuropsychopharmacology*. 2001;25:858-70. doi: 10.1016/S0893-133X(01)00297-4.
- Tedeschi E, Menegazzi M, Margotto D, Suzuki HF, rstermann U, Kleinert H. Anti-inflammatory actions of St. John's wort: inhibition of human inducible nitric oxide synthase expression by down regulating signal transducer and activator of transcription 1 alpha (STAT1alpha) activation. *J Pharmacol Exp Ther*. 2003;307:254-61. doi: 10.1124/jpet.103.054460.
- Linde K. St. John's wort, an overview. *Forsch Komplementmed* 2009;16:146-155. doi: 10.1159/000209290.
- Hubner WD, Kirste T. Experience with St. John's wort (*Hypericum perforatum*) in children under 12 years with symptoms of depression and psychovegetative disturbances. *Phytother. Res*. 2001;15:367-70. doi: 10.1002/ptr.829
- Evsifeeva TA, Sibiriak SV. Immunotropnye svoïstva biologicheskii aktivnykh produktov, poluchennykh iz zverboia prodyriavlennogo [The immunotropic properties of biologically active products obtained from Klamath weed (*Hypericum perforatum* L.)]. *Eksp Klin Farmakol*. 1996 Jan-Feb;59(1):51-4. PMID: 8704635.
- Marbut M, Hadri D, Hadi AM. The effect of oxidative stress on semen parameters of normal and infertile men in Tikrit city. *Tikrit medical J*. 2011;17(1):1-5.
- Bayramoglu G, Bayramoglu A, Engur S, Senturk H, Ozturk N, Colak S. The hepatoprotective effects of *Hypericum perforatum* L. on hepatic ischemia/reperfusion injury in rats. *Cytotechnology*. 2014;66:443-8. doi: 10.1007/s10616-013-9595-x
- De Paola R, Muià C, Mazzon E, Genovese T, Crisafulli C, Menegazzi M, et al. Effects of *Hypericum perforatum* extract in a rat model of ischemia and reperfusion injury. *Shock*. 2005;24:255-63. doi: 10.1097/01.shk.0000175428.57769.34.
- Saija A, Scalese M, Lanza M, Marzullo D, Bonina F, Castelli F. Flavonoids as antioxidant agents: Importance of their interaction with biomembranes. *Free Radic Biol Med*. 1995;19:481-6. doi: 10.1016/0891-5849(94)00240-k.
- Rees A, Dodd GE, Spencer JPE. The effects of flavonoids on cardiovascular health: a review of human intervention trials and implications for cerebrovascular function. *Nutrients*. 2018;10:1852. doi: 10.3390/nu10121852.
- Green DJ, Dawson EA, Groenewoud HM, Jones H, Thijssen DH. Is flow-mediated dilation nitric oxide mediated? A meta-analysis. *Hypertension*. 2014;63:376-82. doi: 10.1161/HYPERTENSIONAHA.113.02044.
- Robert J N, Els Van N, Danny EC. Flavonoids: a review of probable mechanisms of action and potential applications. *Am J Clin Nutr*. 2001;74:418-25. doi: 10.1093/ajcn/74.4.418
- Young JF, Nielsen SE, Haraldsdóttir J, Daneshvar B, Lauridsen ST, Knuthsen P, et al. Effect of fruit juice intake on urinary quercetin excretion and biomarkers of antioxidative status. *Am J Clin Nutr*. 1999;69:87-94. doi: 10.1093/ajcn/69.1.87.
- Corcoran MP, McKay DL, Blumberg JB. Flavonoid basics: chemistry, sources, mechanism of action, and safety. *J Nutr Gerontol Geriatr*. 2012;31:176- 89. doi: 10.1080/21551197.2012.698219
- Peng KZ, Zhang SY, Zhou HL. Toxicological evaluation of the flavonoid-rich extract from *Maydis stigma*: Subchronic toxicity and genotoxicity studies in mice. *J Ethnopharmacol*. 2016;192:161-169. doi: 10.1016/j.jep.2016.07.012.
- Cakir M, Duzova H, Baysal I, Gül CC, Kuşçu G, Kutluk F, et al. The effect of hypericum perforatum on kidney ischemia/reperfusion damage. *Ren Fail*. 2017;39:385-391. doi: 10.1080/0886022X.2017.1287734.
- Kalt W. Effects of production and processing factors on major fruit and vegetable antioxidants. *J Food Sci*. 2005;70:11-9. doi: 10.1111/j.1365-2621.2005.tb09053.x
- Turkmen N, Sari F, Velioglu YS. The effect of cooking methods on total phenolics and antioxidant activity of selected green vegetables. *Food Chem*. 2005;93:713-8. doi: 10.1016/j.foodchem.2004.12.038
- Sharma K, Ko EY, Assefa AD, Ha S, Nile SH, Lee ET, Park SW. Temperature-dependent studies on the total phenolics, flavonoids, antioxidant activities, and sugar content in six onion varieties. *J Food Drug Anal*. 2015;23:243-252. doi: 10.1016/j.jfda.2014.10.005.
- Jiménez-Monreal AM, García-Diz L, Martínez-Tomé M, Mariscal M, Murcia MA. Influence of cooking methods on antioxidant activity of vegetables. *J Food Sci*. 2009;74:97-103. doi: 10.1111/j.1750-3841.2009.01091.x.
- Nicoli MC, Anese M, Parpinel M. Influence of processing on the antioxidant properties of fruit and vegetable. *Trends Food Sci Technol*. 1999;10:94-100. doi: 10.1016/s0924-2244(99)00023-0.
- Yin MC, Cheng WS. Antioxidant activity of several allium members. *J Agric Food Chem*. 1998;46:4097-101.

**Copyright** © 2022 The Author(s); Published by Nickan Research Institute. This is an open-access article distributed under the terms of the Creative Commons Attribution License (<http://creativecommons.org/licenses/by/4.0>), which permits unrestricted use, distribution, and reproduction in any medium, provided the original work is properly cited.